

Picture Index



search



contents



print



last screen viewed



back



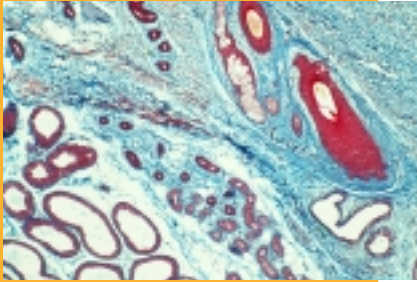
next

basic lesion

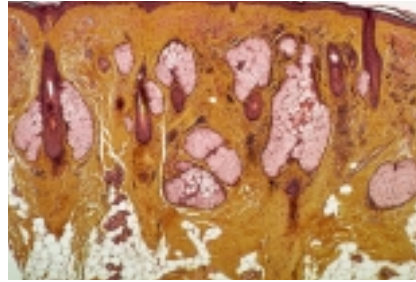
cause

picture

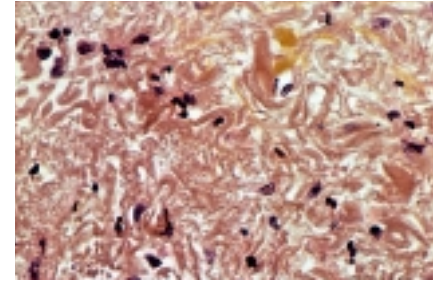
alphabetical



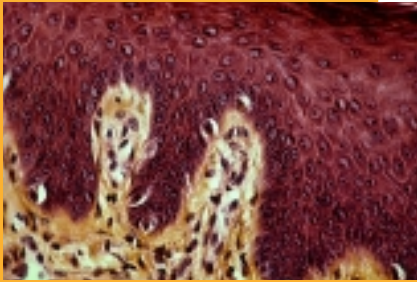
Skin from the axillary region



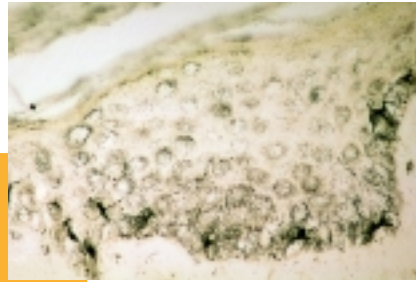
Skin from the forehead region



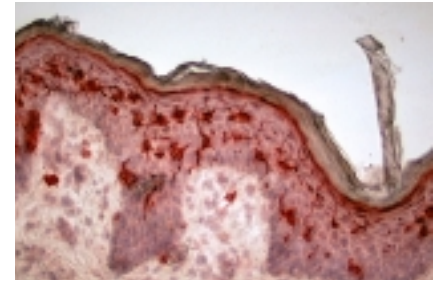
Skin from the face of an elderly subject



Structure of the epidermis



Structure of the epidermis



Structure of the epidermis



search



contents



print



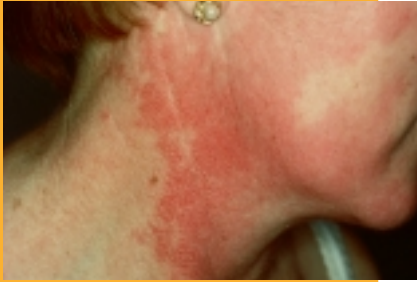last screen viewed



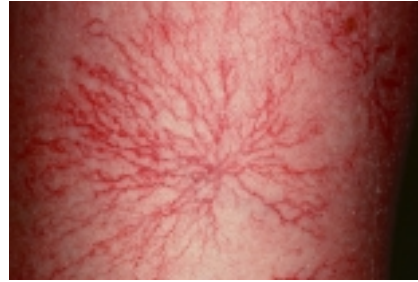back



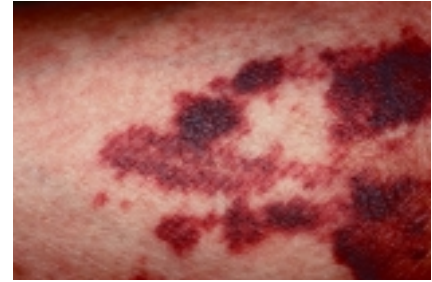next



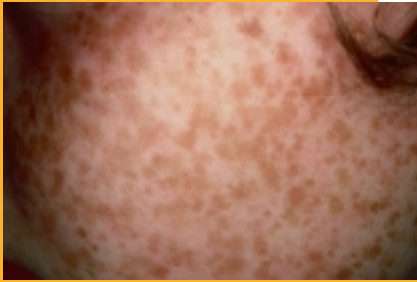Erythematous macule



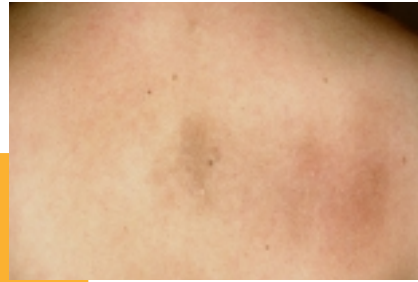Vascular macule



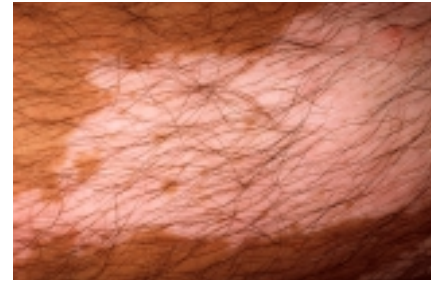Purpuric macule



Pigmentary macules



Pigmentary macules



Pigmentary macules



search



contents



print



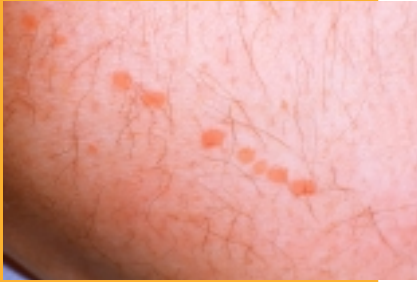last screen viewed



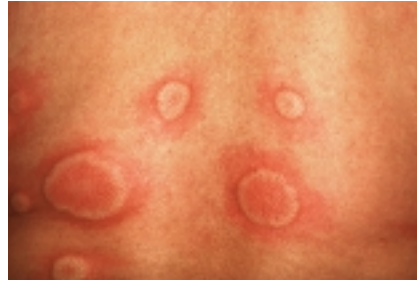back



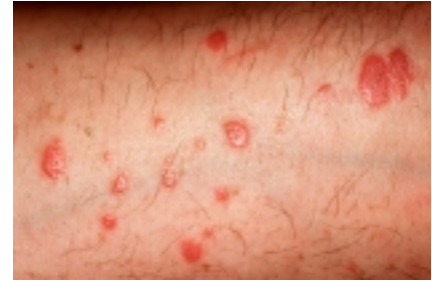next



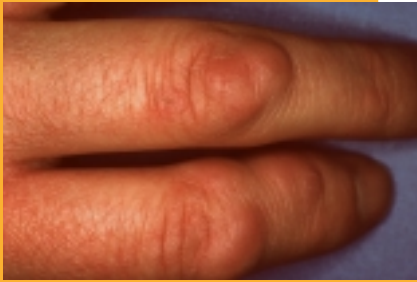Epidermal papules



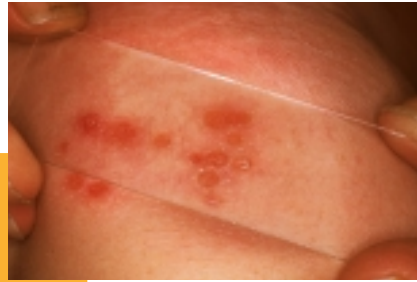Dermal papules



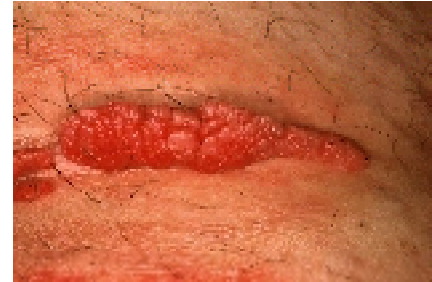Dermo-epidermal papules



Nodules



Tubercles



Vegetations



search



contents



print



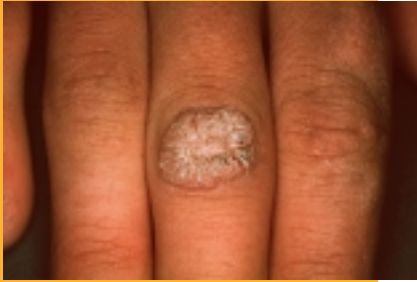last screen viewed



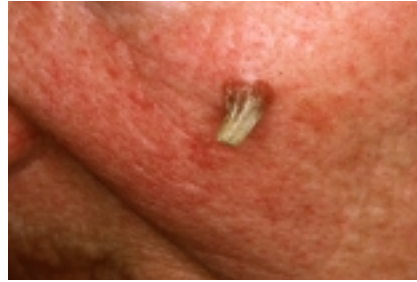back



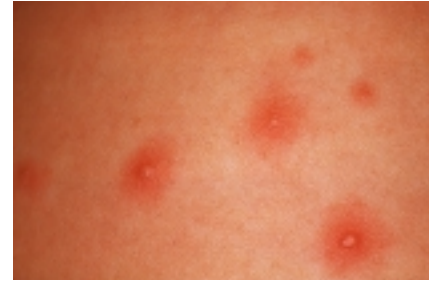next



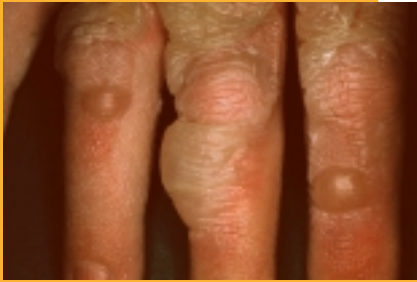Warts



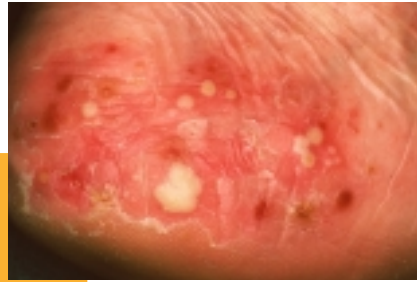
Keratoses



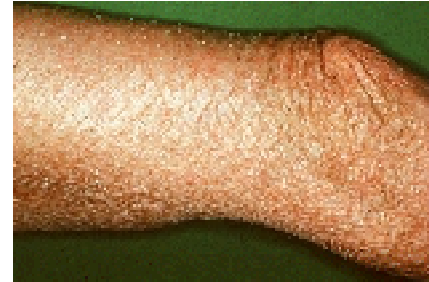Vesicles



Bullae



Pustules



Scales



search



contents



print



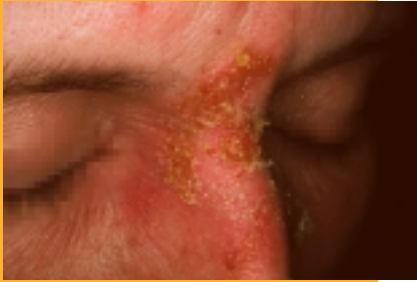last screen viewed



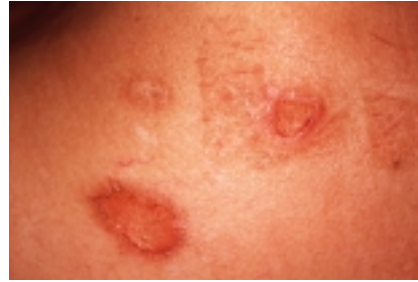back



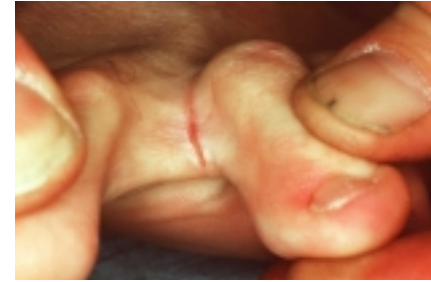next



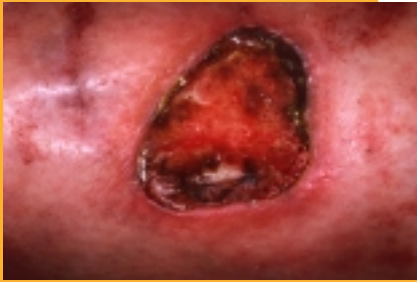
Crusts



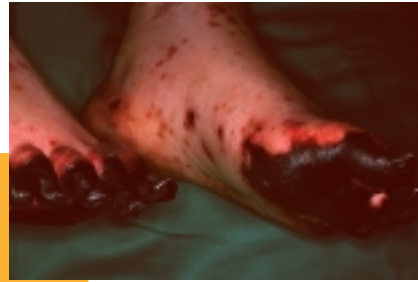Excoriations (or ulcerations)



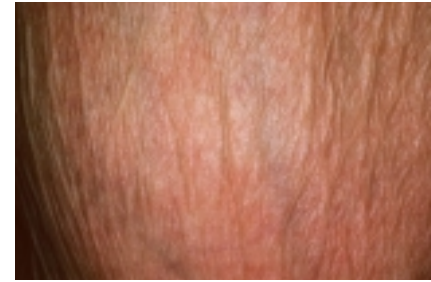Fissures



Ulcers



Gangrene



Atrophy



search



contents



print



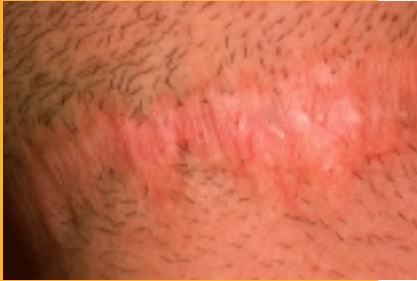last screen viewed



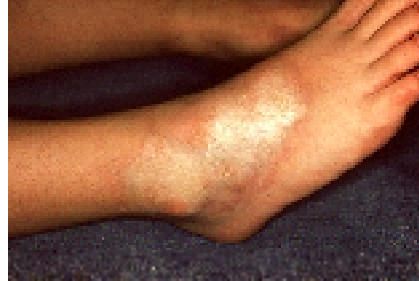back



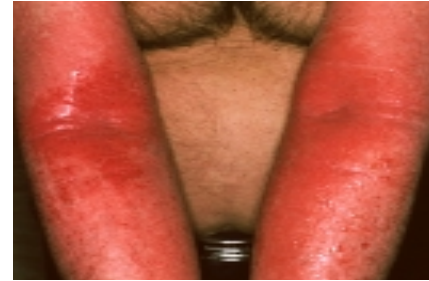next



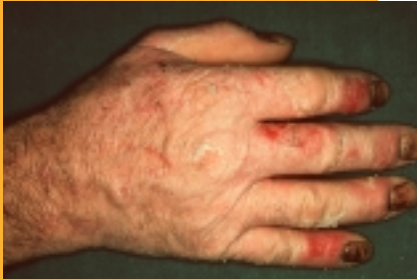Scars



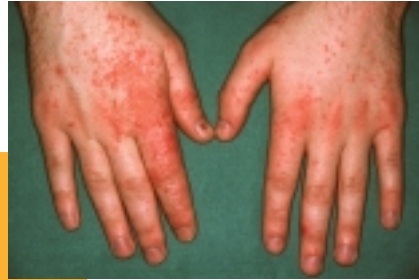Sclerosis



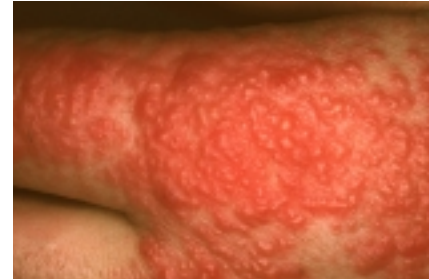Acute exudative contact dermatitis



Chronic occupational contact dermatitis



Vesicular contact dermatitis



Vesicular contact dermatitis



search



contents



print



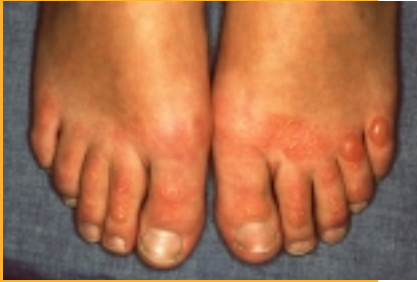last screen viewed



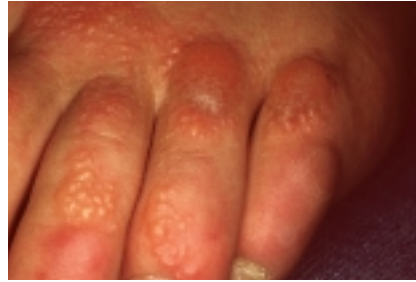back



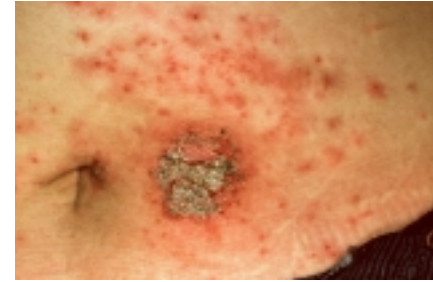next



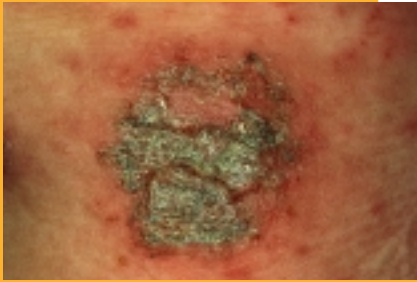Bullous contact dermatitis



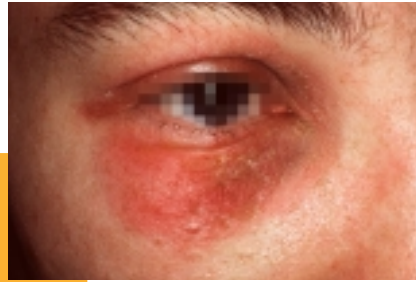Bullous contact dermatitis



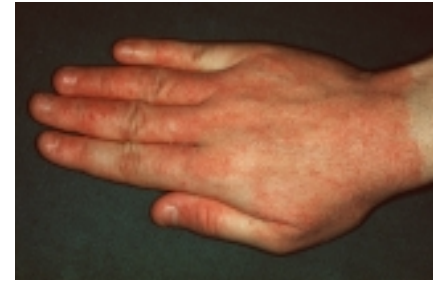Crusted eczema



Crusted eczema



Scaly dry erythematous contact dermatitis



Acute irritant dermatitis



search



contents



print



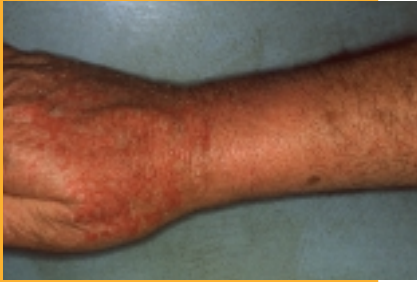last screen viewed



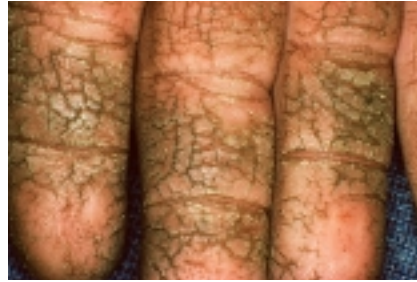back



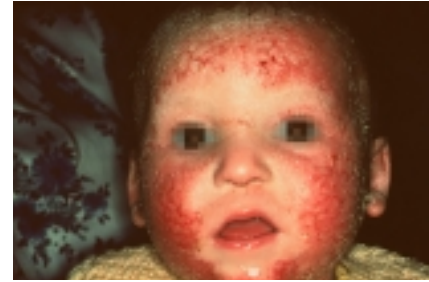next



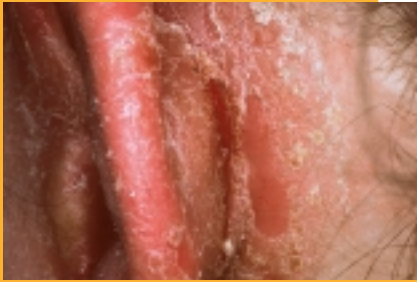Cumulative insult dermatitis



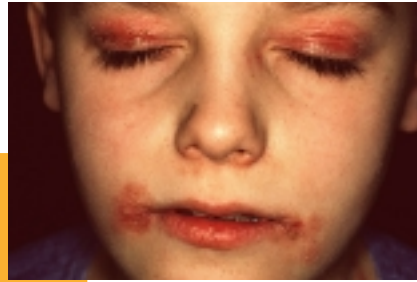Chronic palmar irritant dermatitis



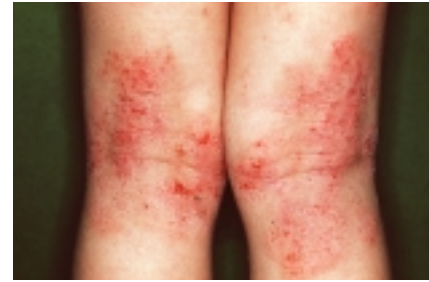Atopic dermatitis of the face in an infant



Infected retro-auricular dermatitis



Atopic dermatitis of childhood



Atopic dermatitis of the folds in a child



search



contents



print



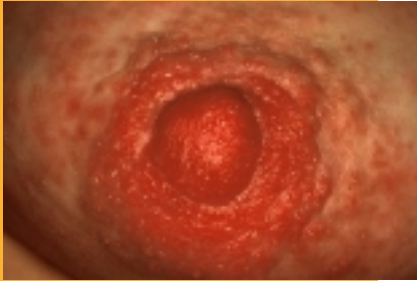last screen viewed



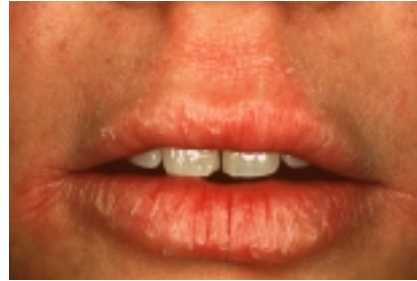back



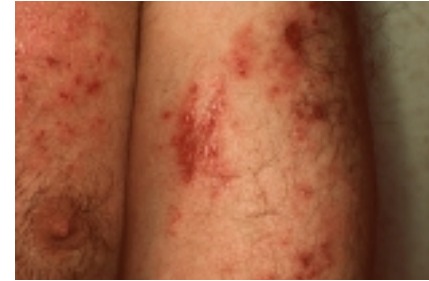next



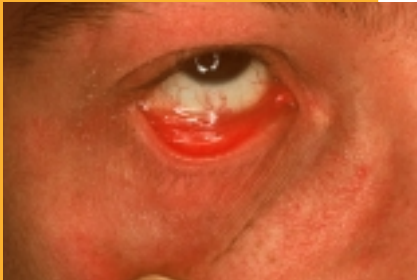Eczema of the nipples



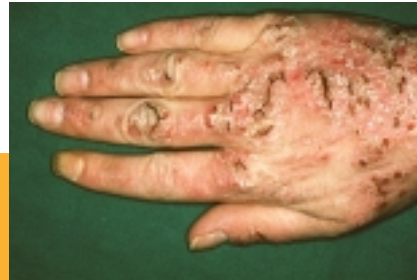Atopic cheilitis



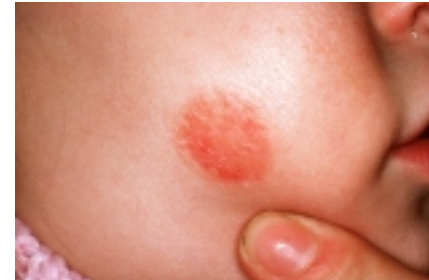Atopic dermatitis in the adult



Atopic conjunctivitis



Atopic dermatitis of the hands in the adult



Pityriasis alba



search



contents



print



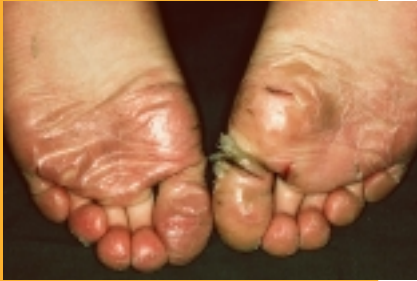last screen viewed



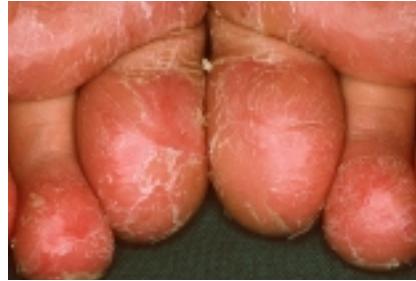back



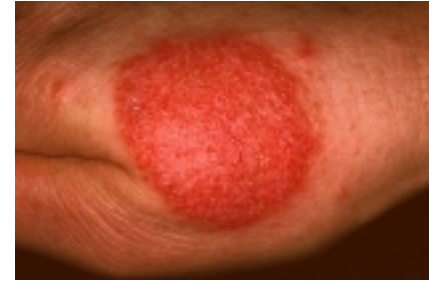next



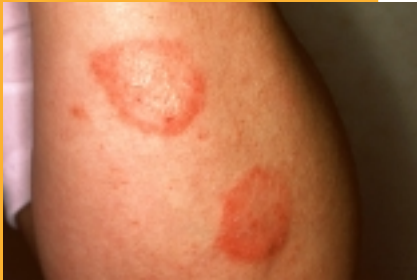Juvenile plantar dermatosis



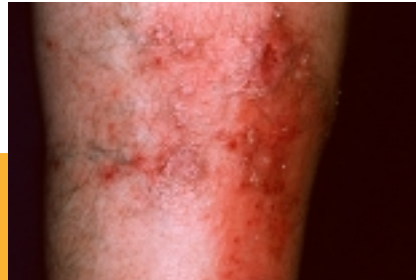Juvenile plantar dermatosis



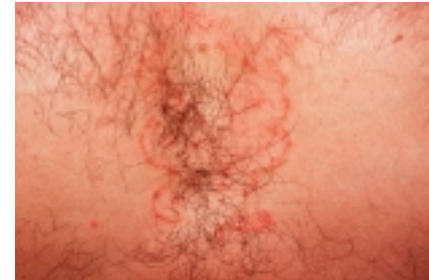Nummular dermatitis



Nummular dermatitis



Gravitational eczema



Seborrhoeic dermatitis of the trunk



search



contents



print



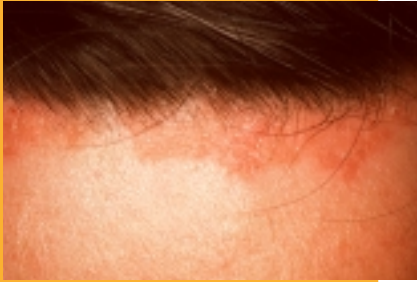last screen viewed



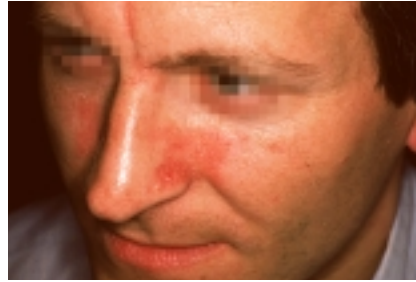back



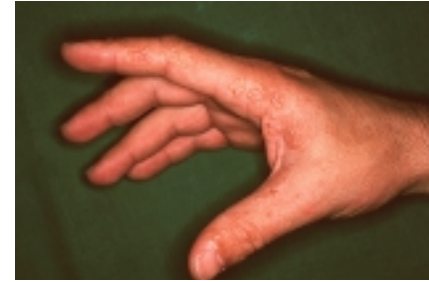next



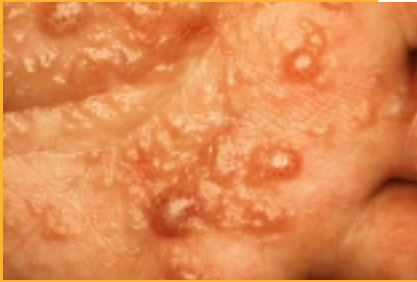Seborrhoeic dermatitis of the hairline



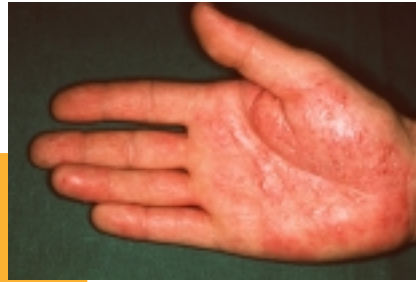Seborrhoeic dermatitis of the face



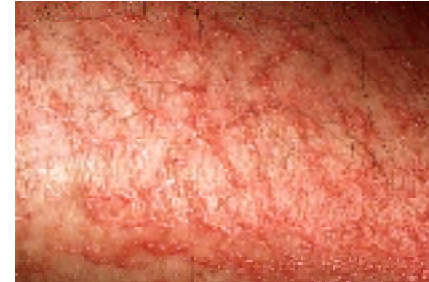Pompholyx of the fingers



Bullous pompholyx of the palms



Eczematous pompholyx of the palms



Asteatotic eczema



search



contents



print



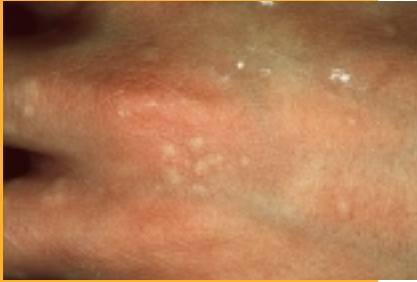
last screen viewed



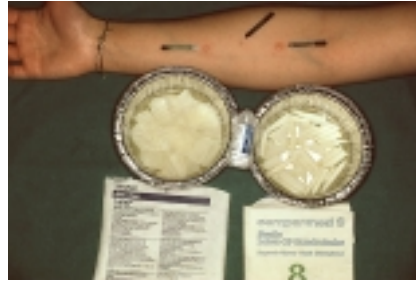back



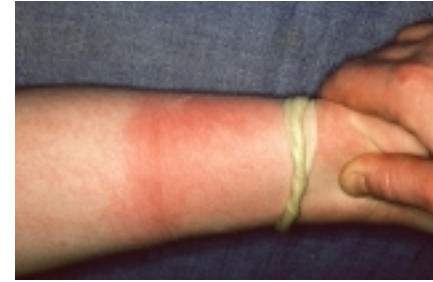next



Latex contact urticaria



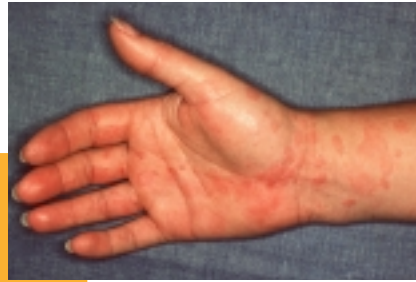Prick test with latex



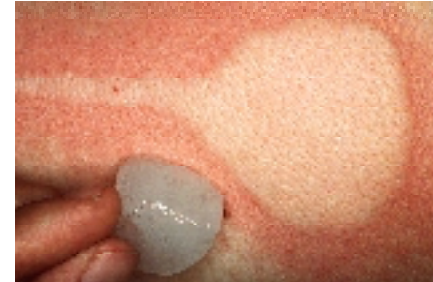Provocative use test with latex gloves



Dermographism



Pressure urticaria



Cold urticaria



search



contents



print



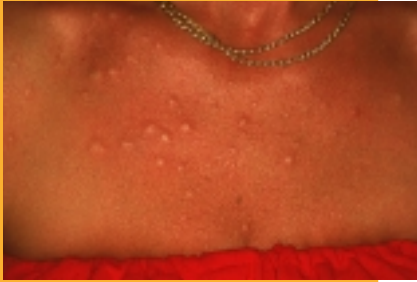last screen viewed



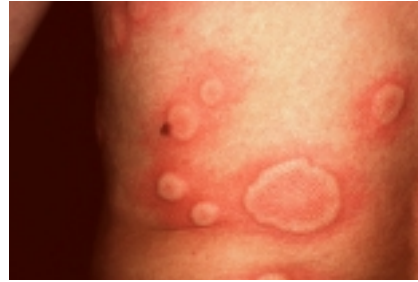back



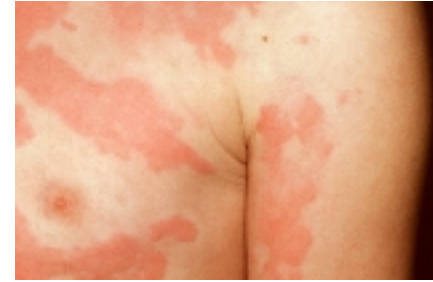next



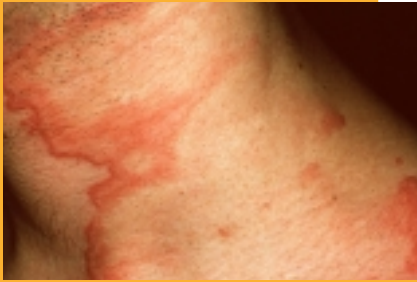Solar urticaria



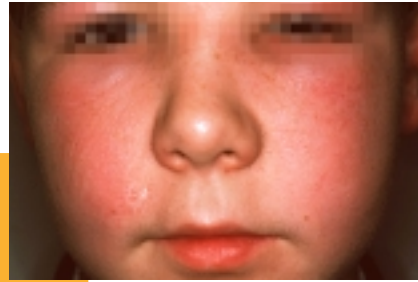Urticated weals



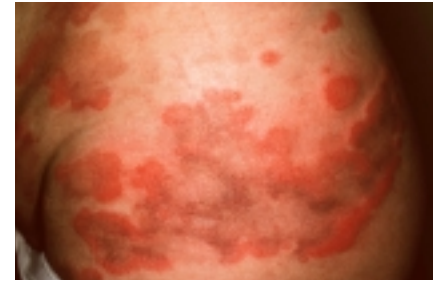
Papular urticaria



Figured urticaria



Hereditary angio-oedema



Urticarial vasculitis



search



contents



print



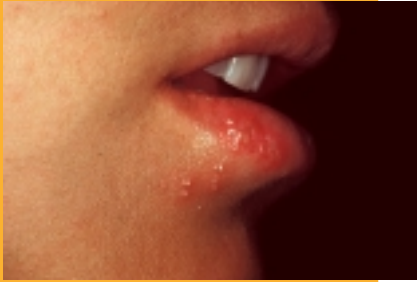last screen viewed



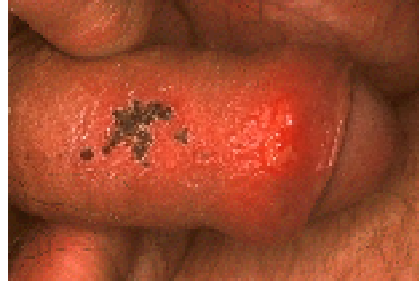back



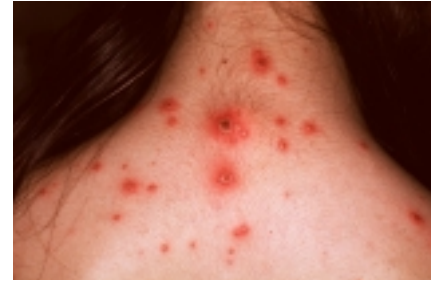next



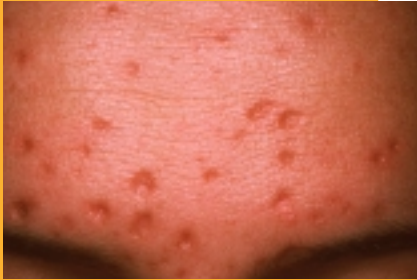Herpes, type I



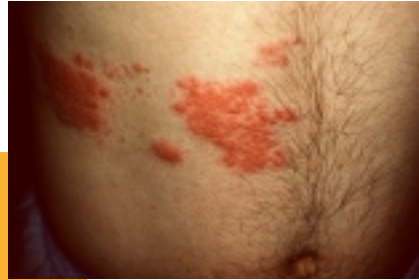Herpes, type II (genital)



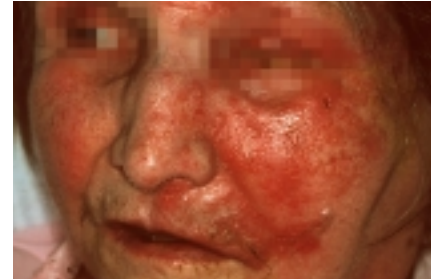Varicella



Varicella



Zoster of the trunk



Ophthalmic nerve zoster



search



contents



print



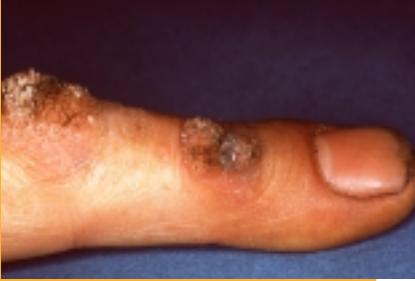last screen viewed



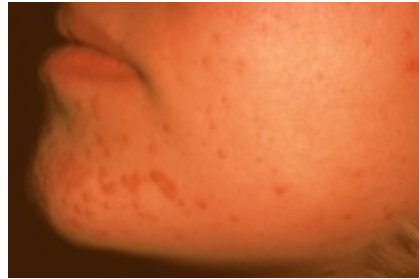back



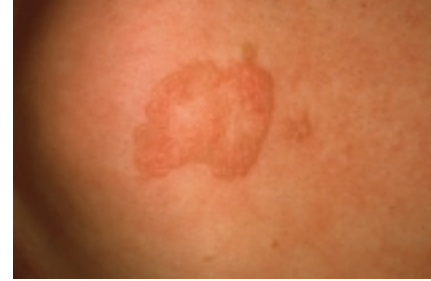next



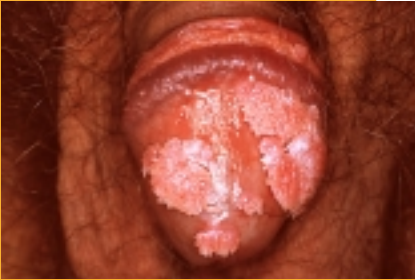Common warts



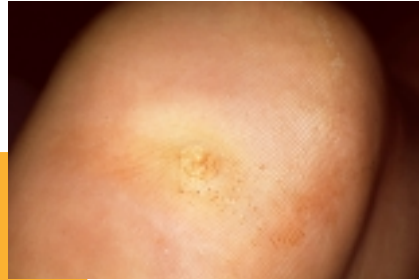
Plane warts



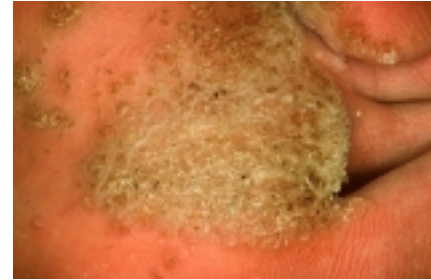
Plane warts



Condylomata acuminata



Plantar wart



Mosaic warts



search



contents



print



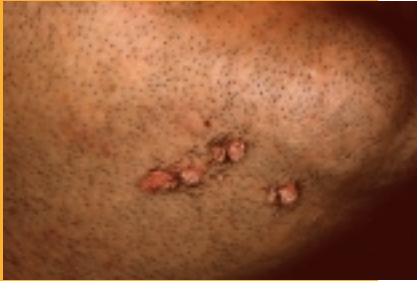last screen viewed



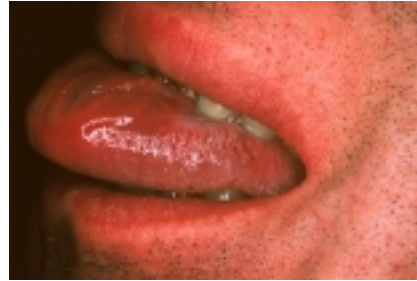back



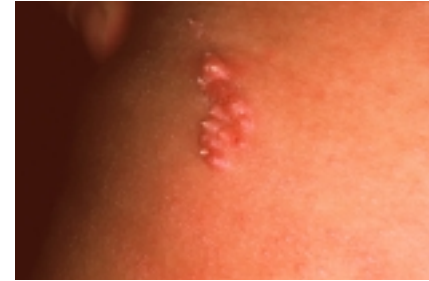next



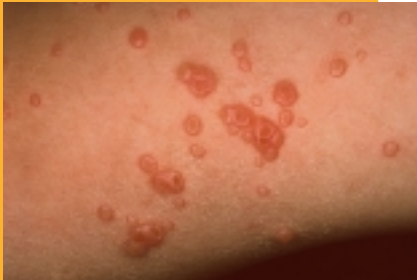Horny filiform wart



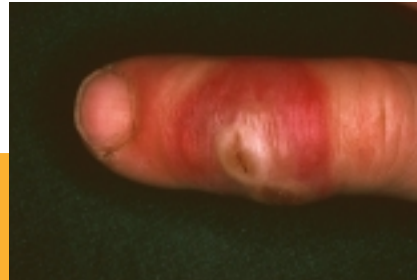Hairy leukoplakia



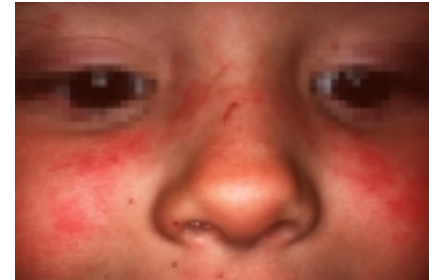Molluscum contagiosum



Multiple mollusca contagiosa



ORF



Erythema infectiosum



search



contents



print



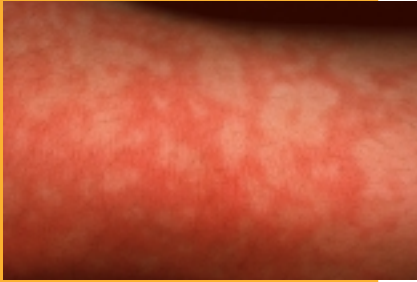
last screen viewed



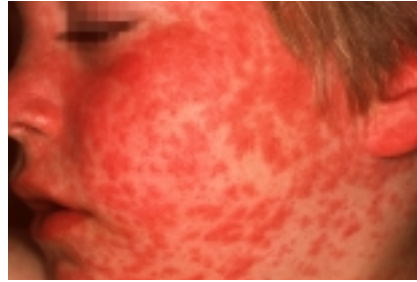
back



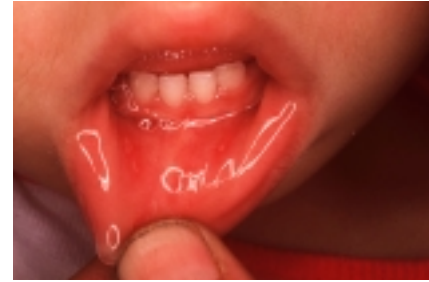next



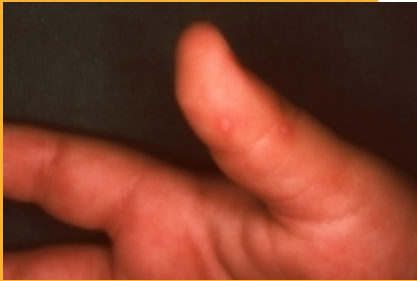Erythema infectiosum



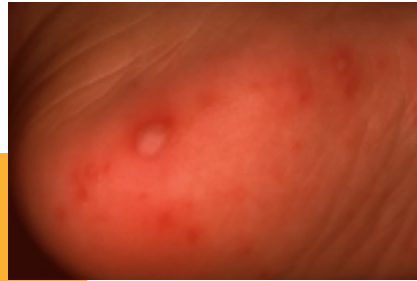
Measles



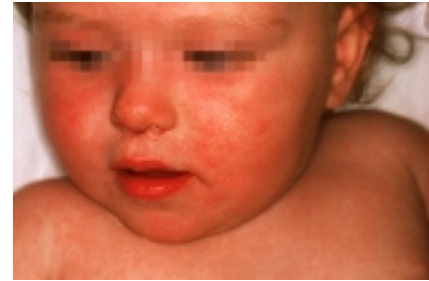Hand-foot-and-mouth-disease



Hand-foot-and-mouth-disease



Hand-foot-and-mouth-disease



Rubella



search



contents



print



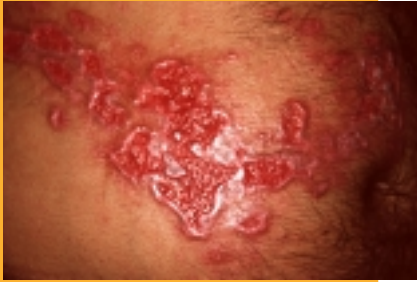last screen viewed



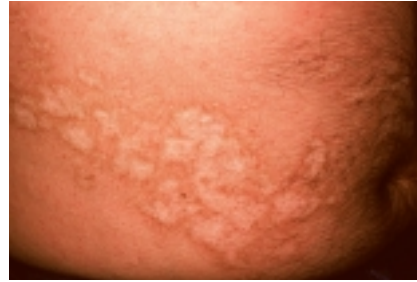
back



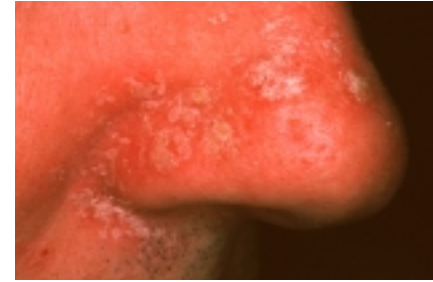
next



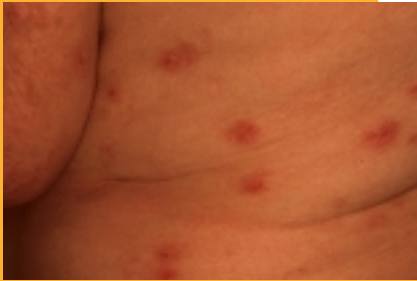Necrotic herpes zoster



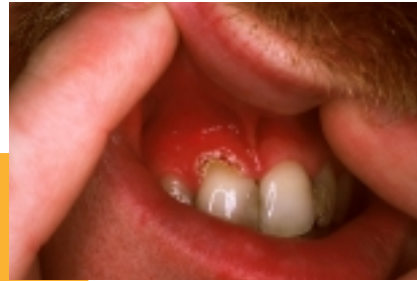Necrotic herpes zoster



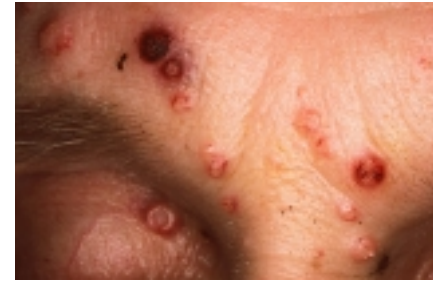Seborrhoeic dermatitis



Prurigo



Gingivitis



Molluscum contagiosum



search



contents



print



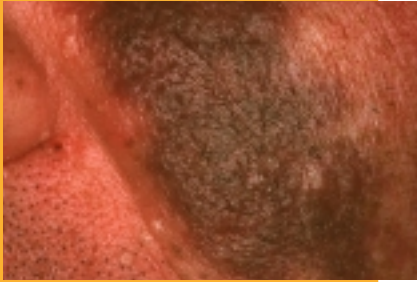
last screen viewed



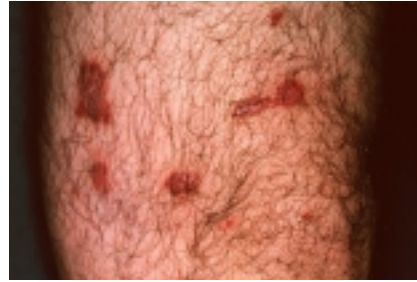back



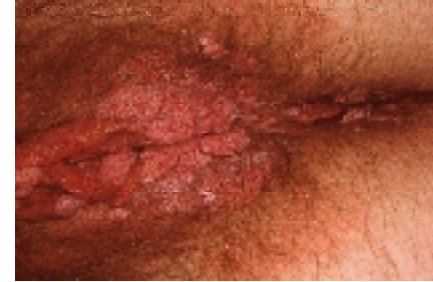next



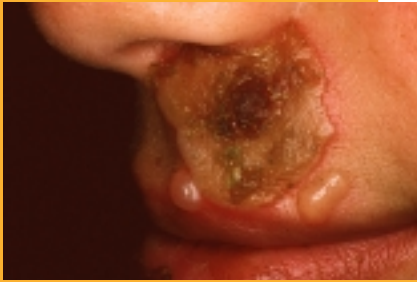Kaposi's sarcoma



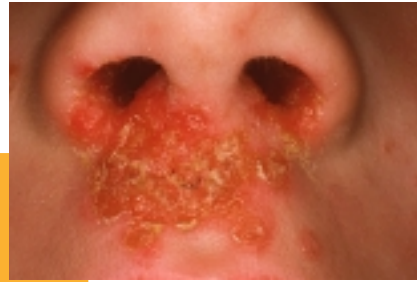Kaposi's sarcoma



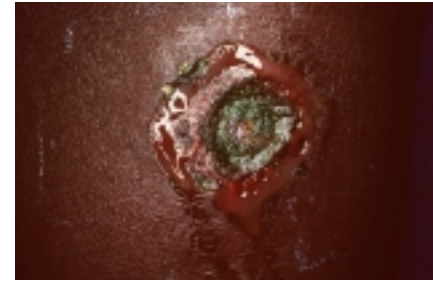
Condylomata acuminata



Bullous impetigo



Non-bullous impetigo



Ecthyma



search



contents



print



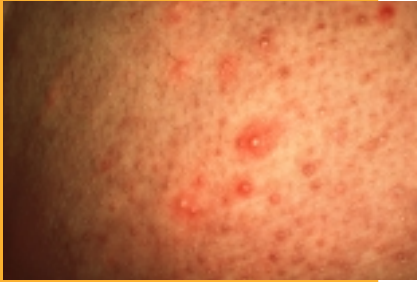last screen viewed



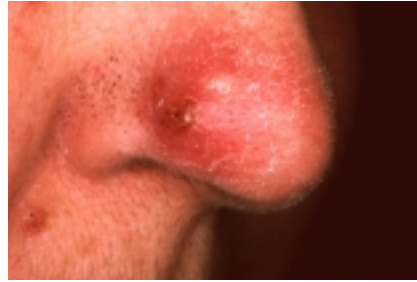back



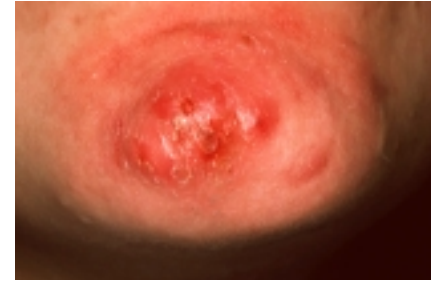next



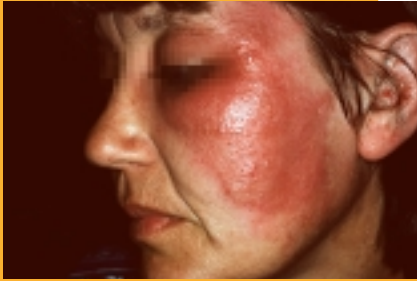Folliculitis



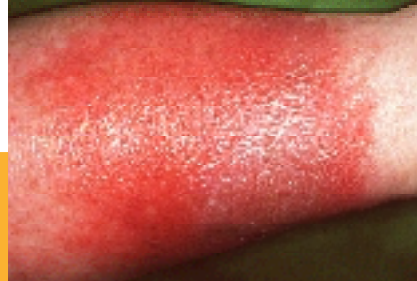Furuncle (BOIL)



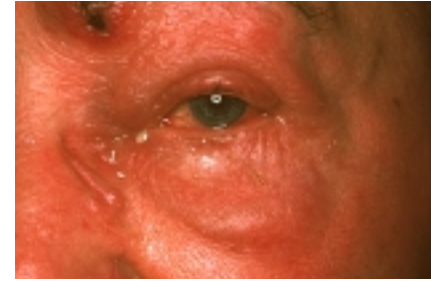
Carbuncle



Erysipelas



Erysipelas



Orbital cellulitis



search



contents



print



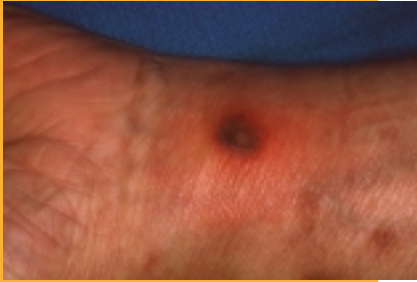last screen viewed



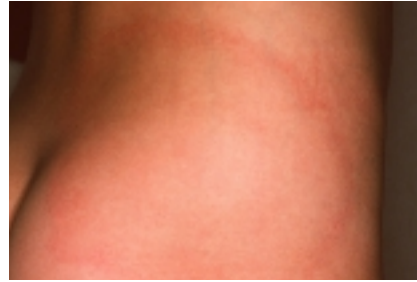back



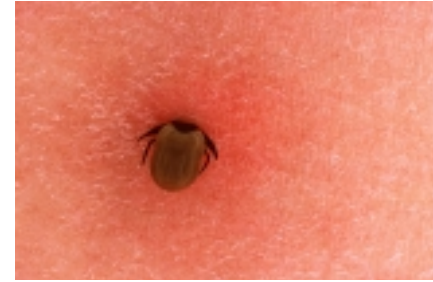next



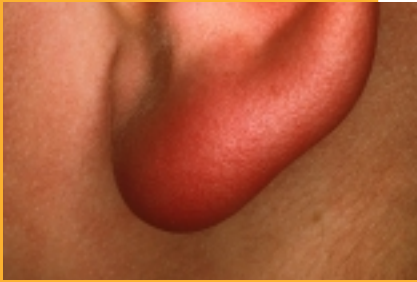Septic emboli



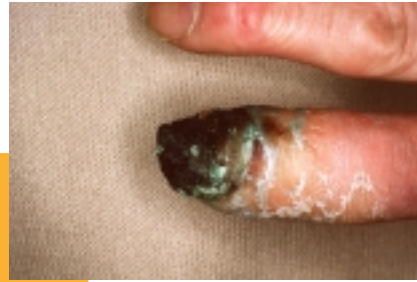Erythema chronicum migrans



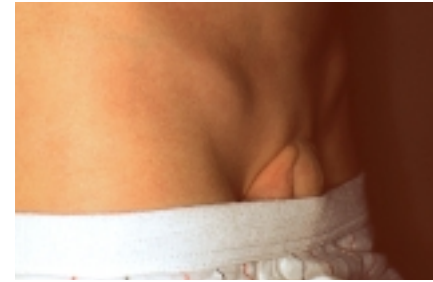Erythema chronicum migrans



Borrelia pseudolymphoma



Proteus infection



Cat-scratch disease



search



contents



print



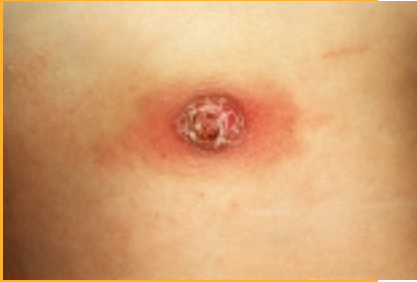last screen viewed



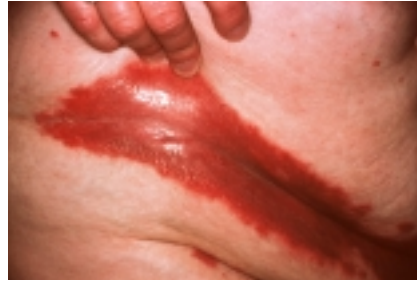back



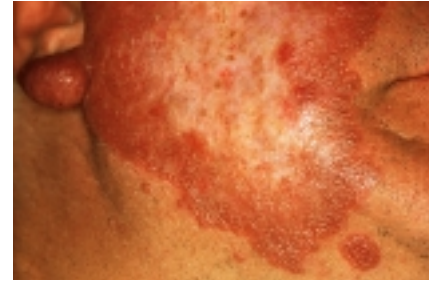next



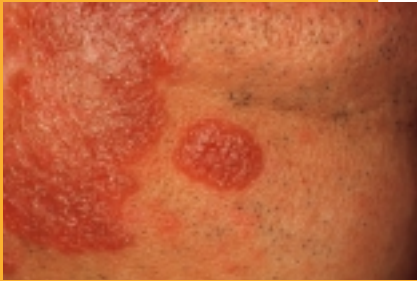Cat-scratch disease



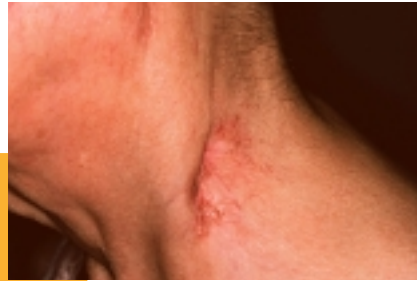Intertrigo



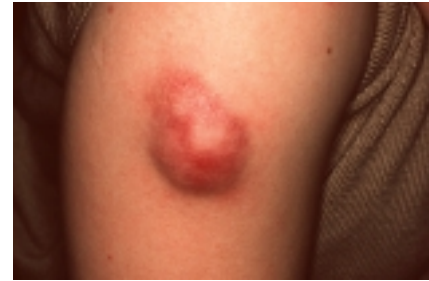Lupus vulgaris



Lupus vulgaris



Scrofuloderma



Complication of BCG vaccination



search



contents



print



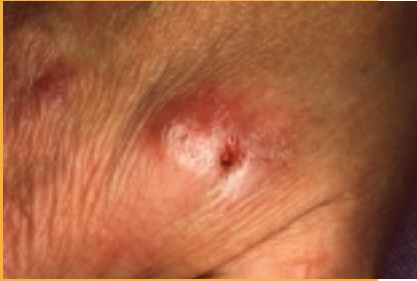last screen viewed



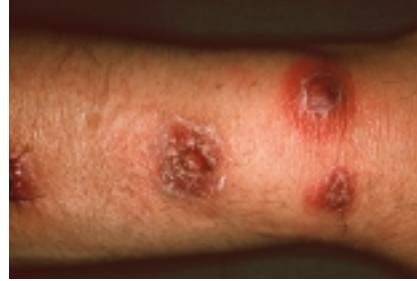back



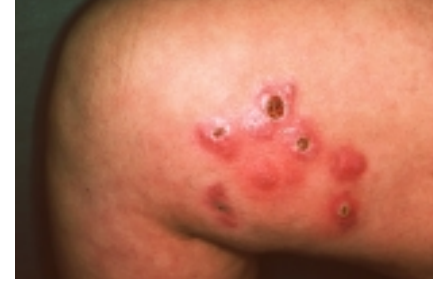next



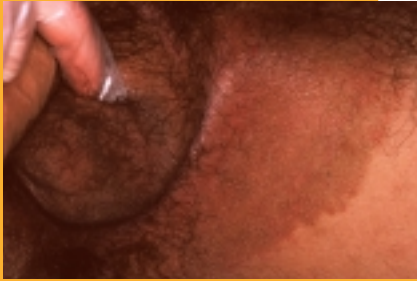Infection with mycobacterium marinum



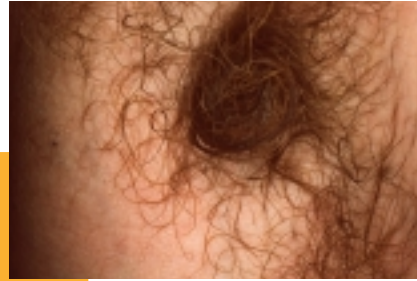Infection with mycobacterium marinum



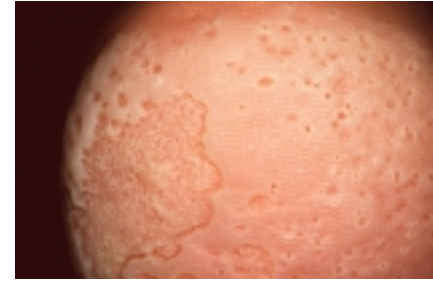
Infection with mycobacterium fortuitum or chelonae



Erythrasma



Trichomycosis axillaris



Pitted keratolysis



search



contents



print



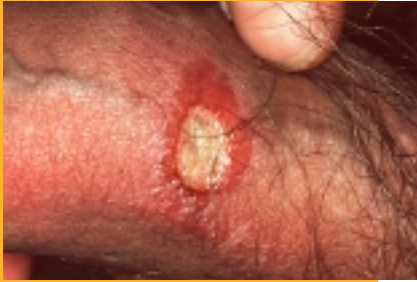last screen viewed



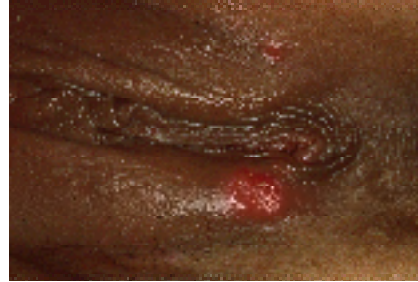back



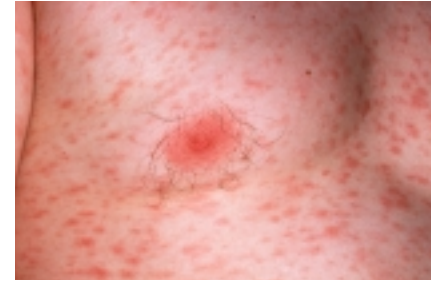next



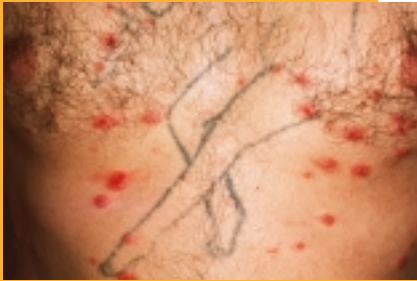Syphilitic chancre
(primary sore)



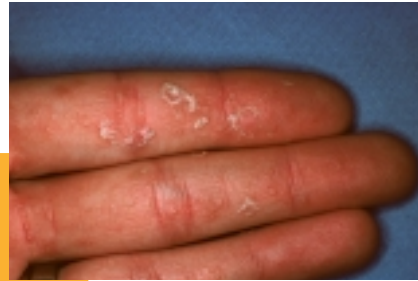Syphilitic chancre
(primary sore)



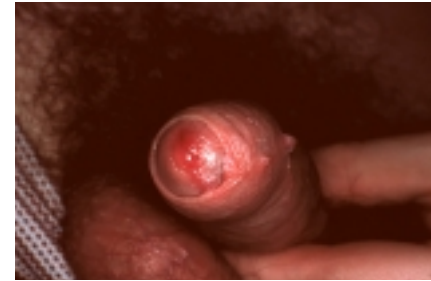Secondary syphilis



Late secondary syphilis



Papular syphilids



Genital gonorrhoea



search



contents



print



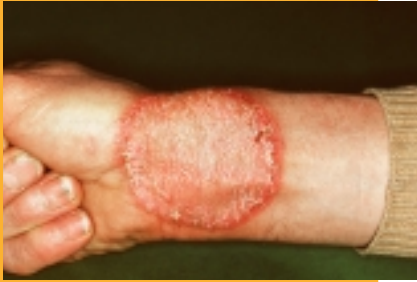last screen viewed



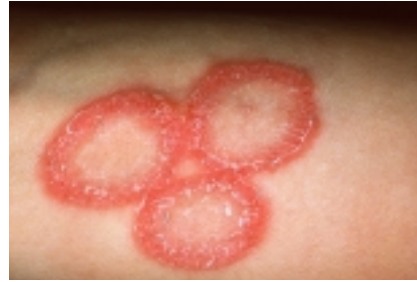back



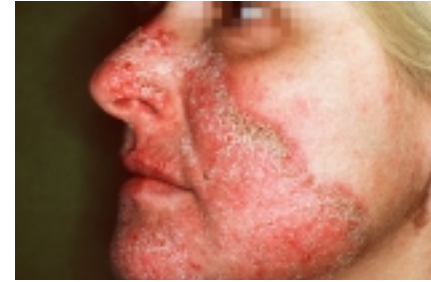next



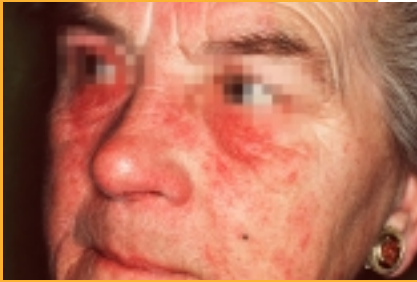Tinea corporis



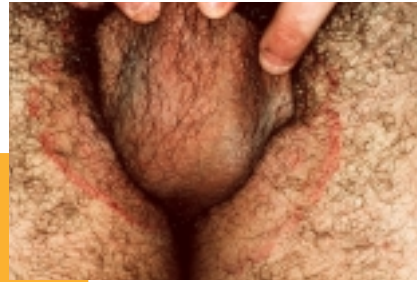Tinea corporis



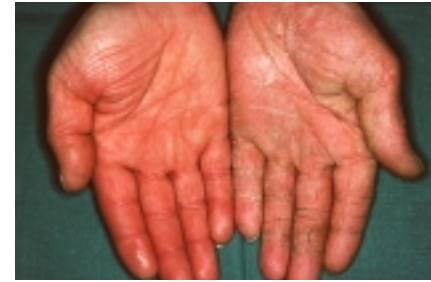Tinea faciei



Tinea faciei



Tinea cruris



Tinea manuum



search



contents



print



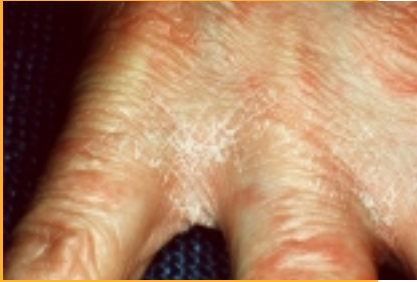last screen viewed



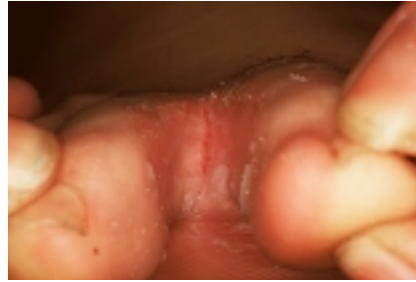back



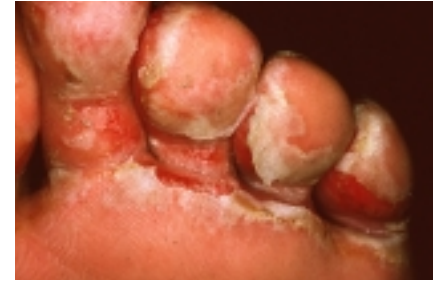next



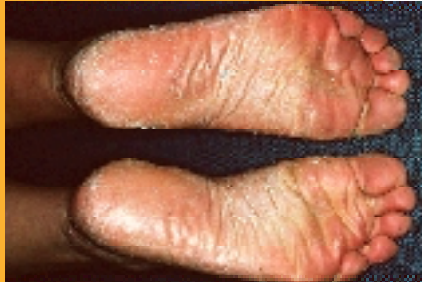Tinea manuum



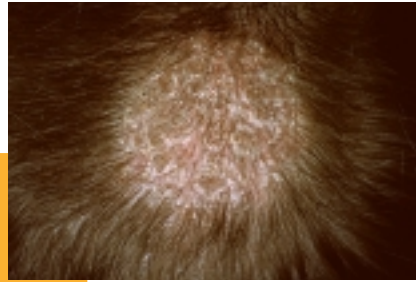Tinea pedum (athlete's foot)



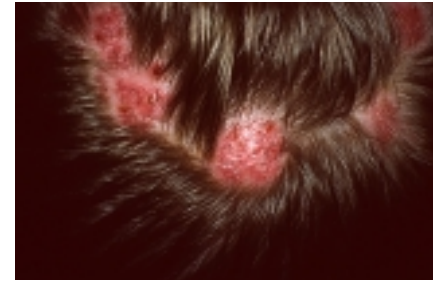Tinea pedum (athlete's foot)



Tinea pedum (athlete's foot)



Tinea capitis or ringworm



Kerion



search



contents



print



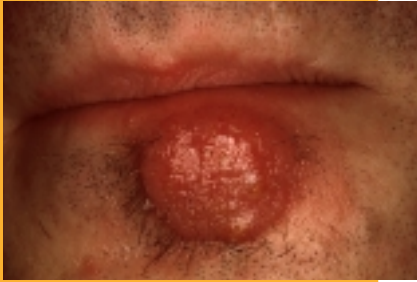last screen viewed



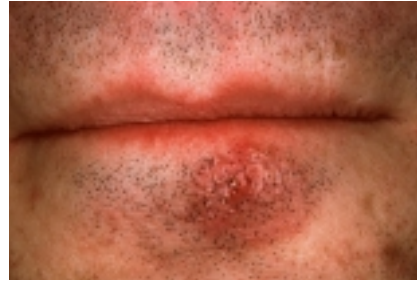back



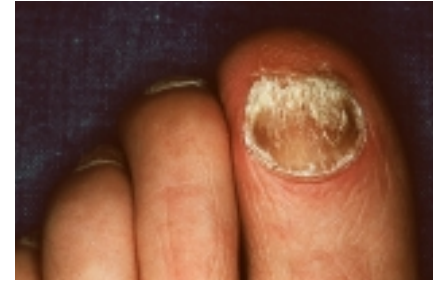next



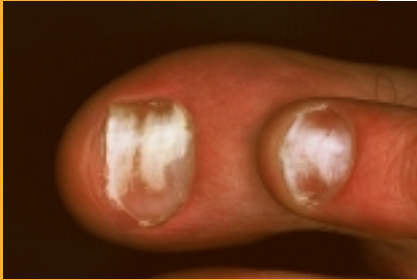Kerion



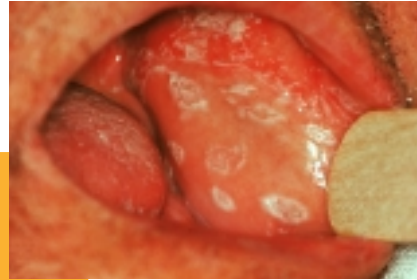
Kerion



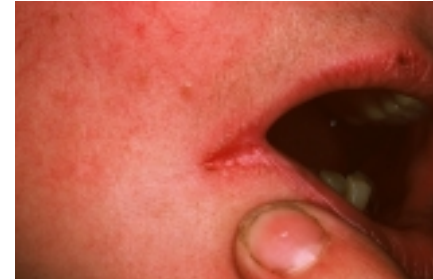Onychomycosis due to dermatophytes



Onychomycosis due to dermatophytes



Thrush



Angular cheilitis



search



contents



print



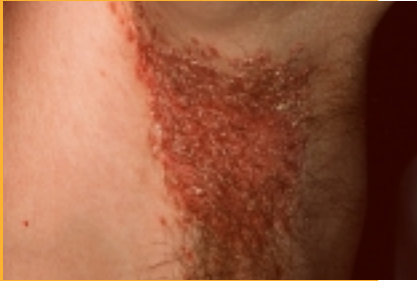last screen viewed



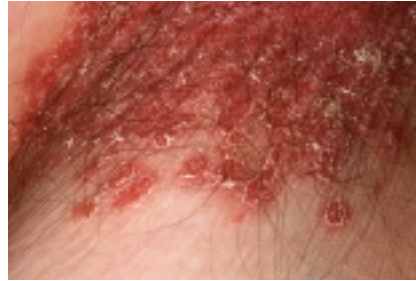back



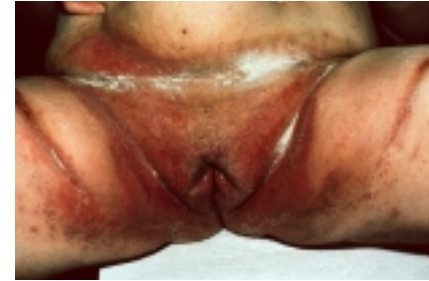next



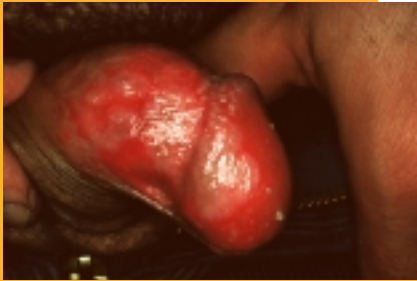Candidal intertrigo



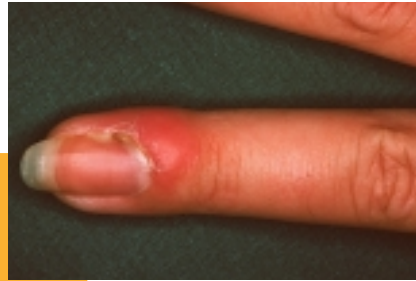Candidal intertrigo



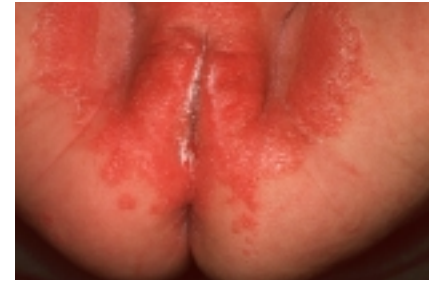Candidal vulvovaginitis



Candidal balanitis



Candidal paronychia and subungual infection



Napkin candidiasis (infant)



search



contents



print



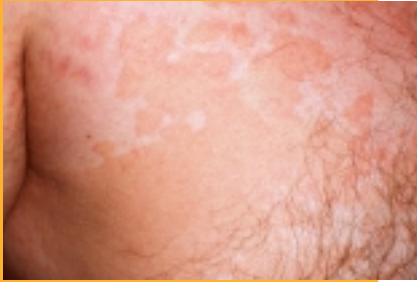last screen viewed



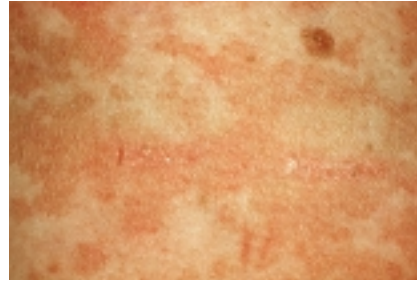back



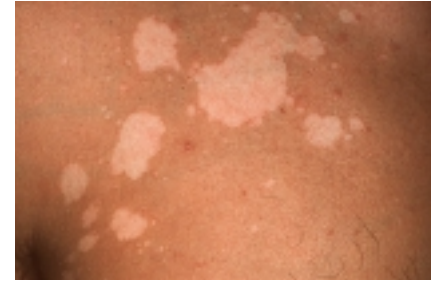next



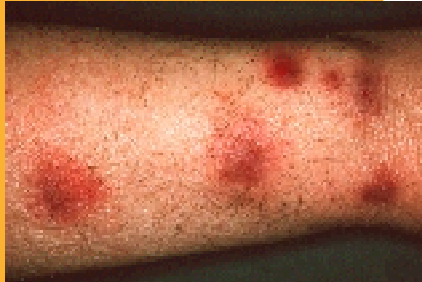Pityriasis versicolor



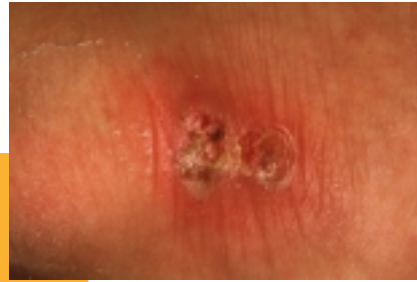Pityriasis versicolor



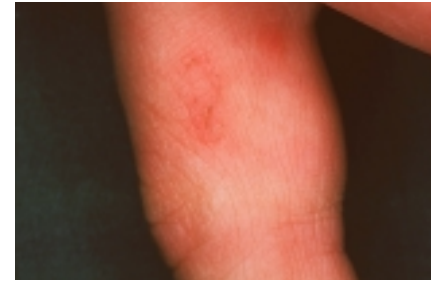
Pityriasis versicolor



Sporotrichosis



Mycetoma (Madura foot)



Human scabies



search



contents



print



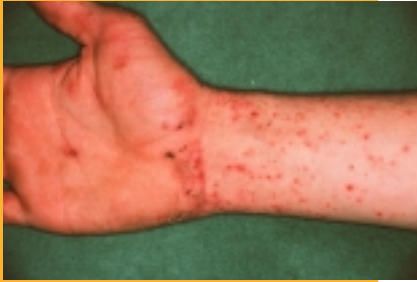last screen viewed



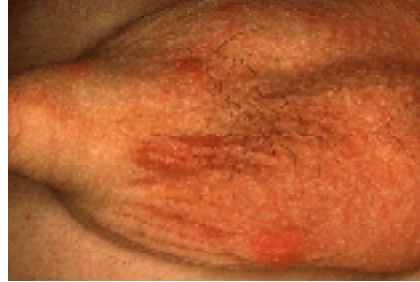back



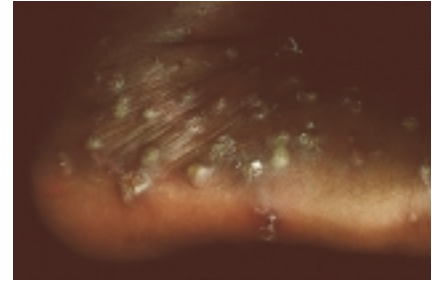next



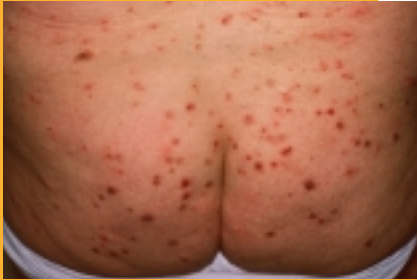Human scabies



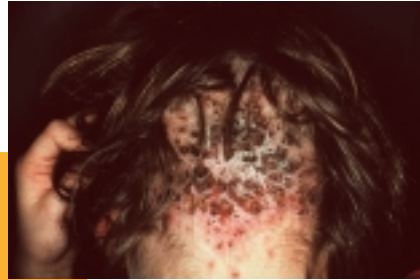Human scabies



Human scabies



Animal scabies



Pediculosis (head lice)



Pediculosis (head lice)



search



contents



print



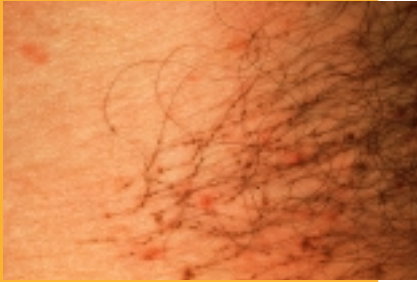last screen viewed



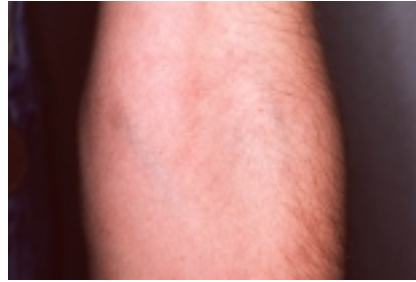
back



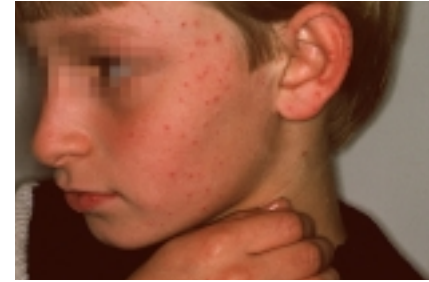next



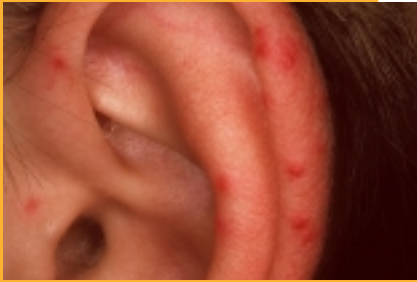Crab lice (pubic lice)



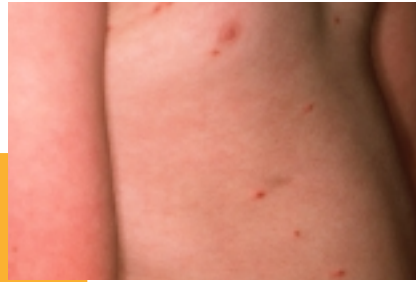Crab lice (pubic lice)



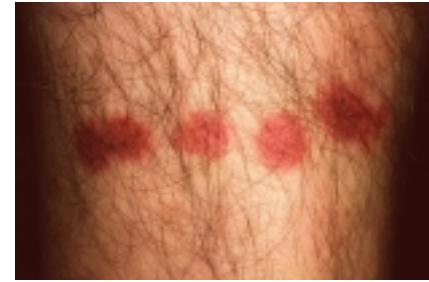Trombiculiasis



Trombiculiasis



Infantile papular urticaria (strophulus)



Flea bites



search



contents



print



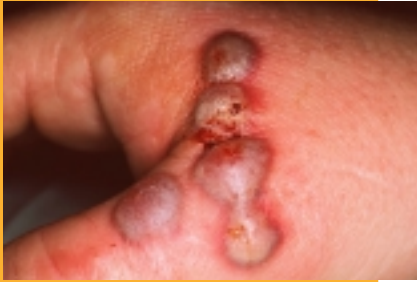last screen viewed



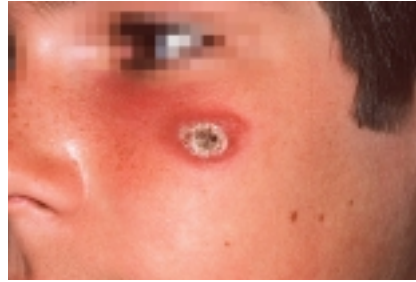back



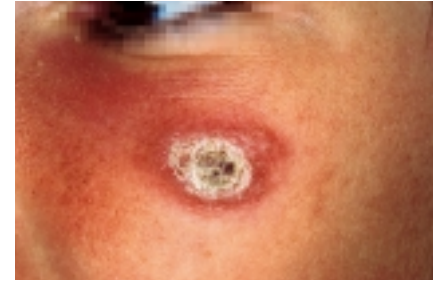next



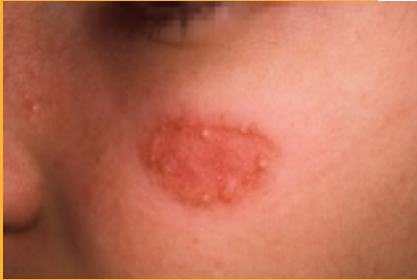Flea bites



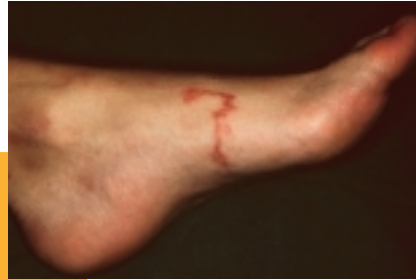Leishmaniasis



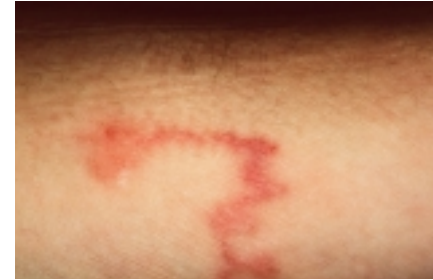Leishmaniasis



Leishmaniasis



Larva migrans
(creeping eruption)



Larva migrans
(creeping eruption)



search



contents



print



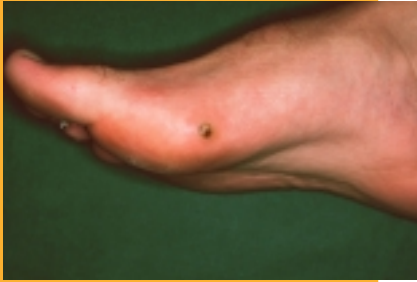last screen viewed



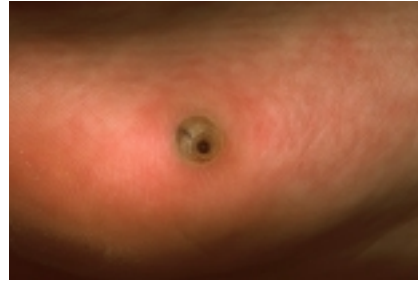back



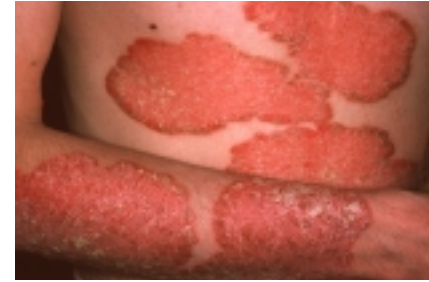next



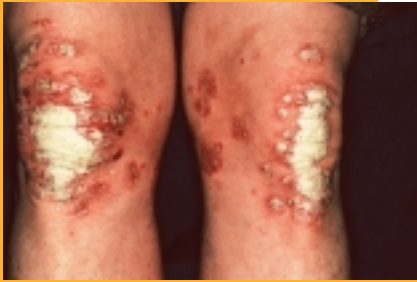Tungiasis (chigger)



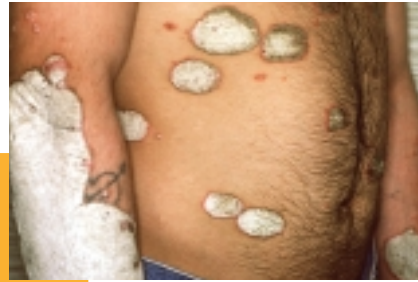Tungiasis (chigger)



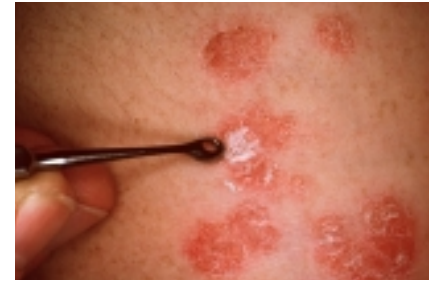Psoriasis vulgaris



Psoriasis vulgaris



Psoriasis vulgaris



Psoriasis vulgaris



search



contents



print



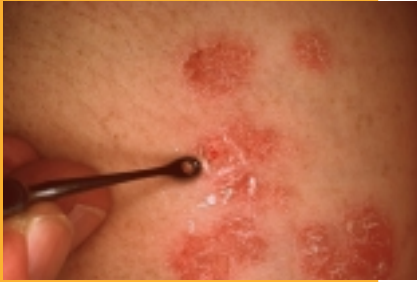last screen viewed



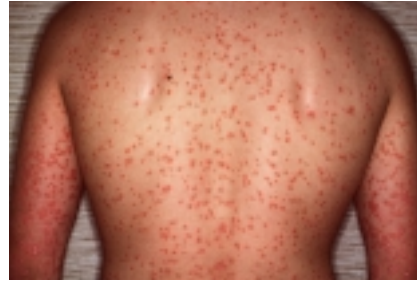back



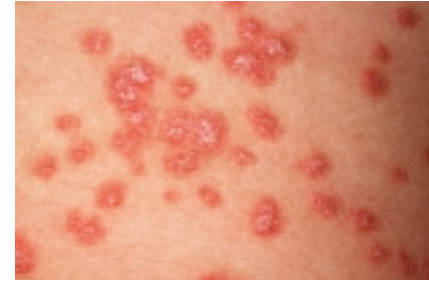next



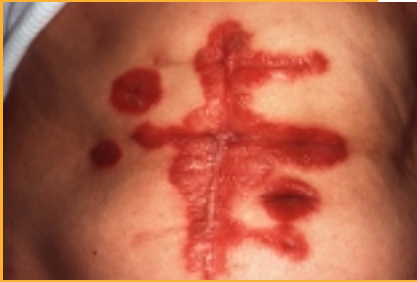Psoriasis vulgaris



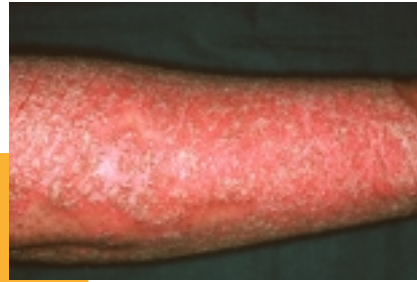Psoriasis vulgaris



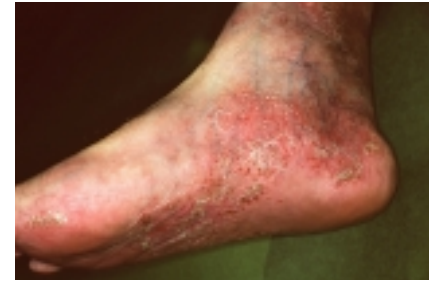Psoriasis vulgaris



Psoriasis vulgaris



Pustular psoriasis



Pustular psoriasis



search



contents



print



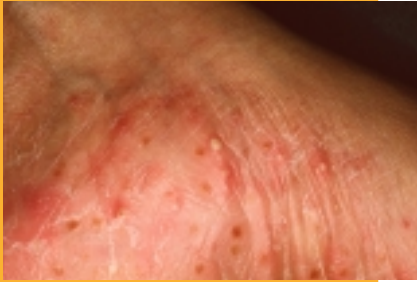last screen viewed



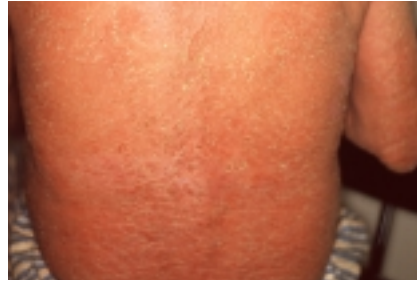back



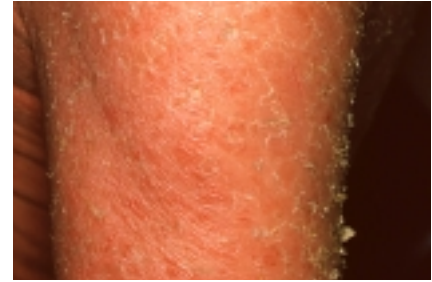
next



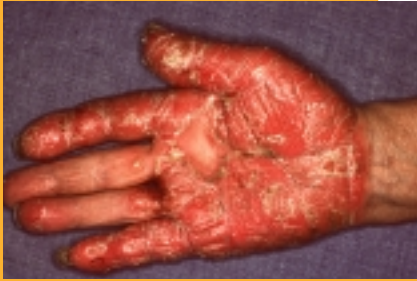Pustular psoriasis



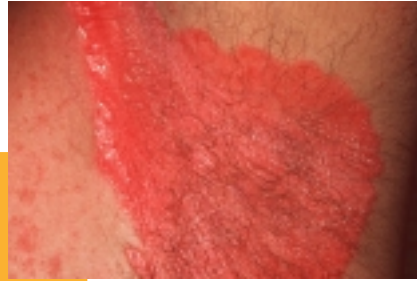Psoriatic erythroderma



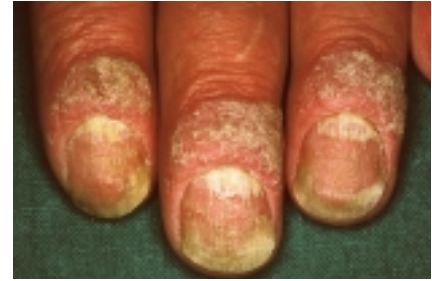Psoriatic erythroderma



Palmoplantar psoriasis



Flexural psoriasis



Psoriasis of the nails



search



contents



print



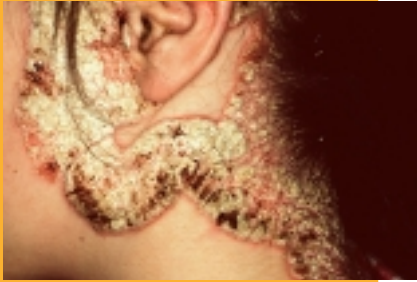last screen viewed



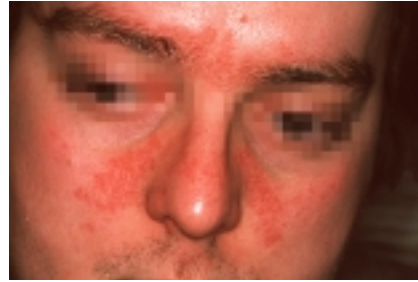back



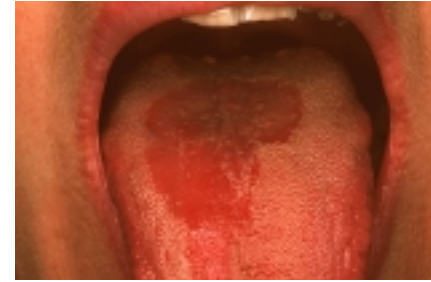next



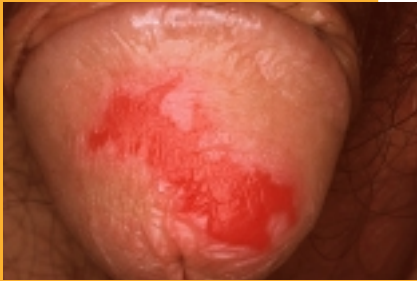Psoriasis of the scalp



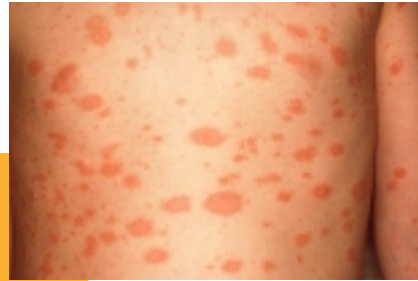Psoriasis of the face



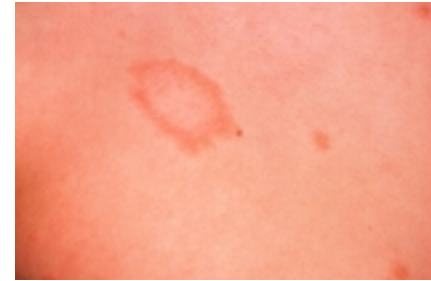Mucosal psoriasis



Mucosal psoriasis



Pityriasis rosea



Pityriasis rosea



search



contents



print



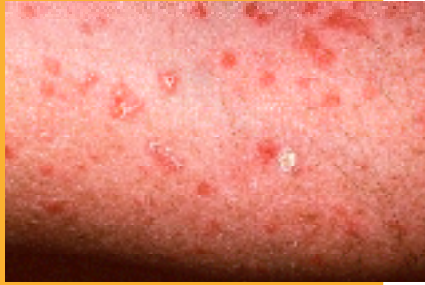last screen viewed



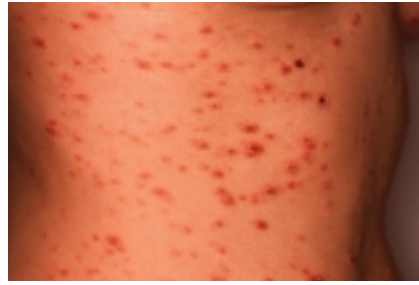back



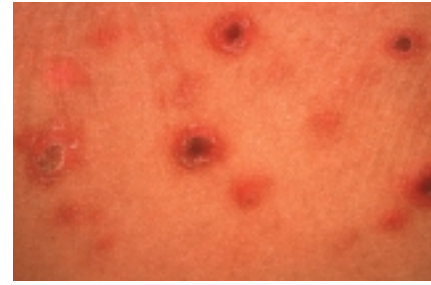
next



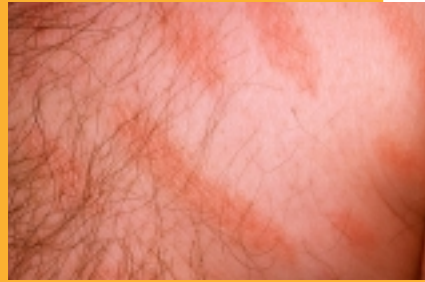Pityriasis lichenoides



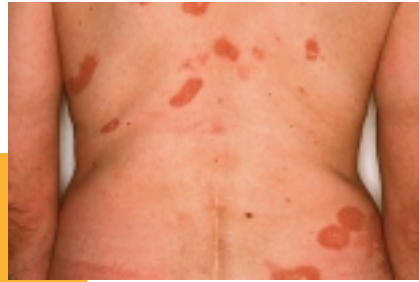Varioloid parapsoriasis



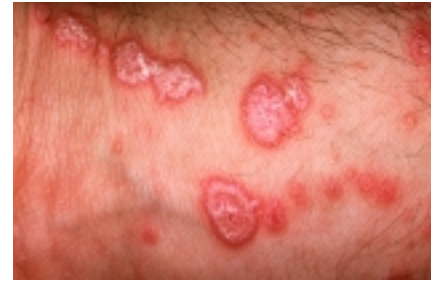Varioloid parapsoriasis



Chronic superficial scaly dermatitis



Premycotic



Simple cutaneous lichen planus



search



contents



print



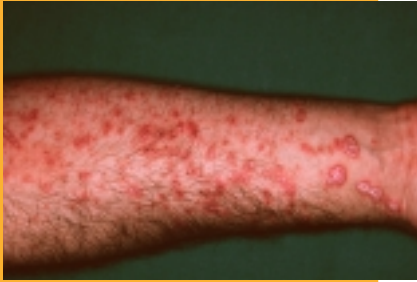last screen viewed



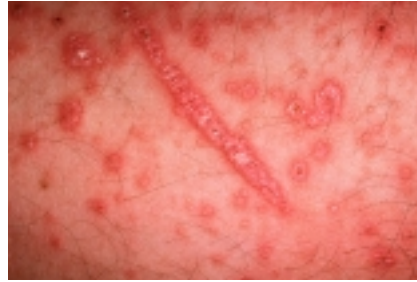back



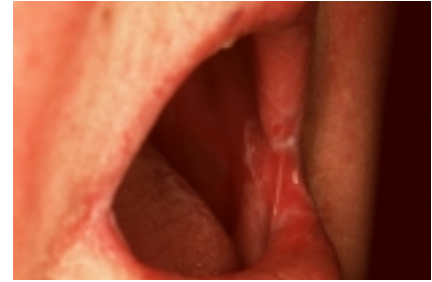next



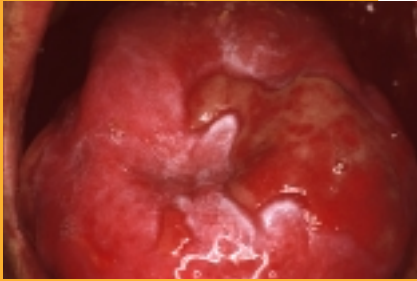Simple cutaneous lichen planus



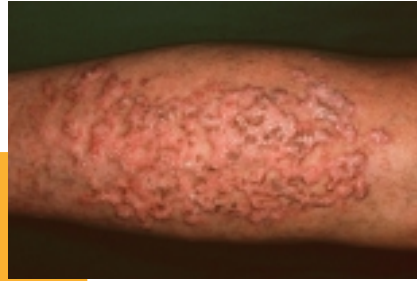Simple cutaneous lichen planus



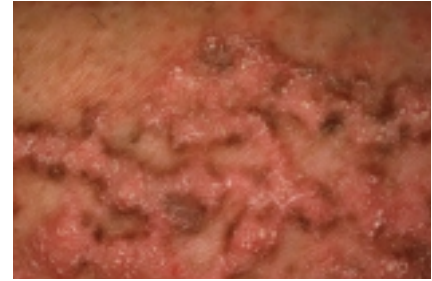
Oral lichen planus



Oral lichen planus



Hypertrophic lichen planus



Hypertrophic lichen planus



search



contents



print



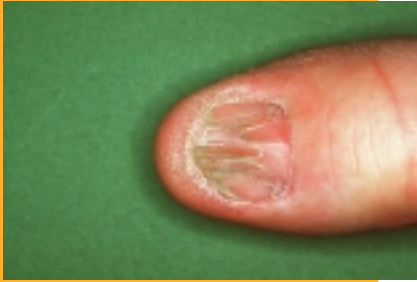last screen viewed



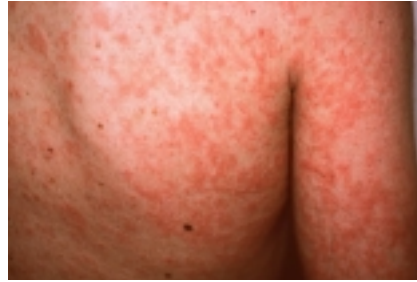back



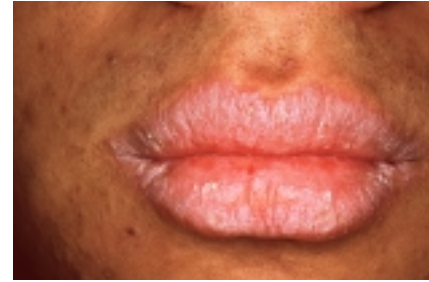next



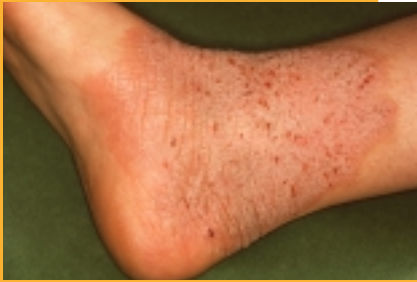Lichen planus of the nails



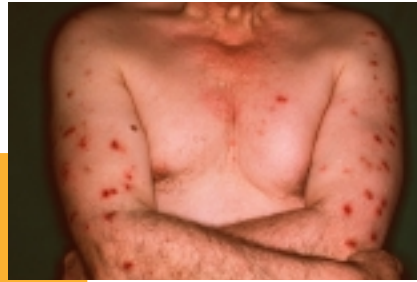Graft versus host disease



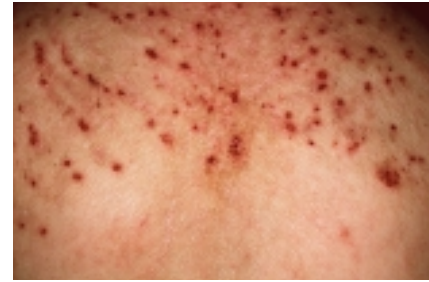Graft versus host disease



Lichenification



Subacute prurigo



Subacute prurigo



search



contents



print



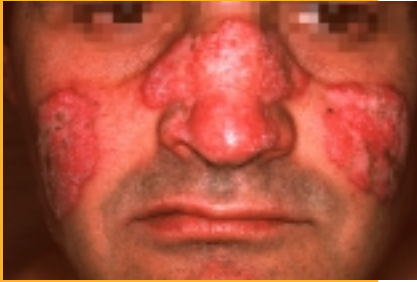last screen viewed



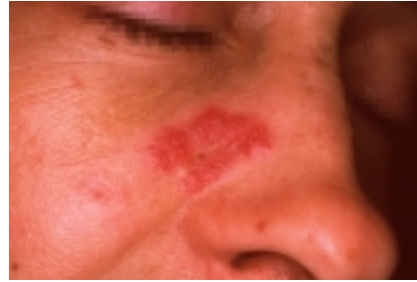back



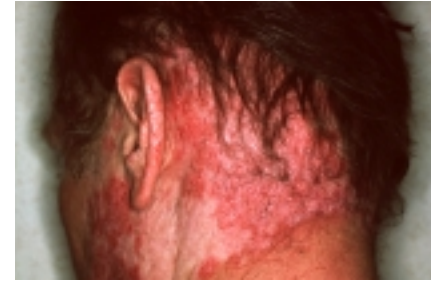next



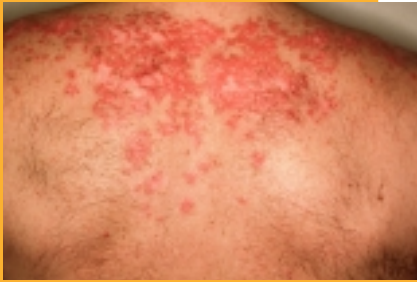Discoid lupus erythematosus



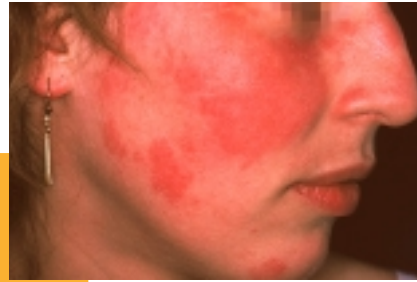Discoid lupus erythematosus



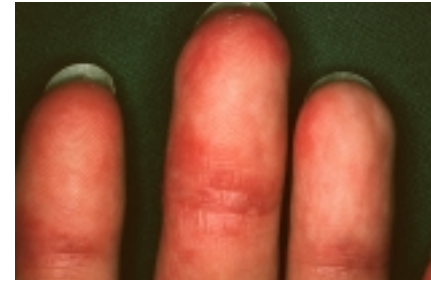Discoid lupus erythematosus



Subacute lupus erythematosus



Systemic lupus erythematosus



Systemic lupus erythematosus



search



contents



print



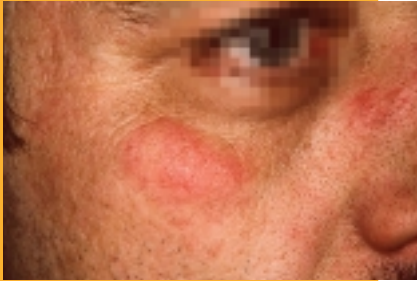last screen viewed



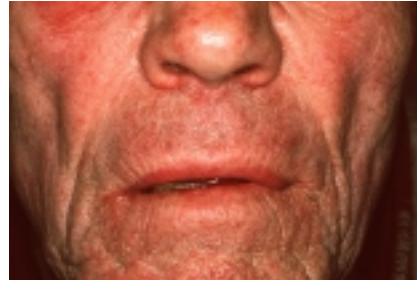back



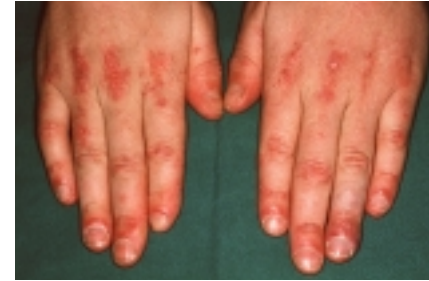next



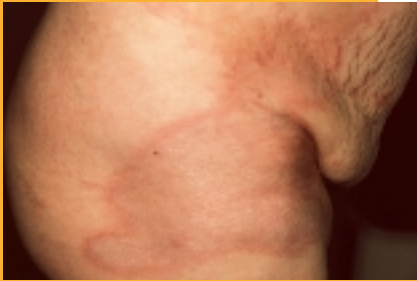Jessner and Kanof disease



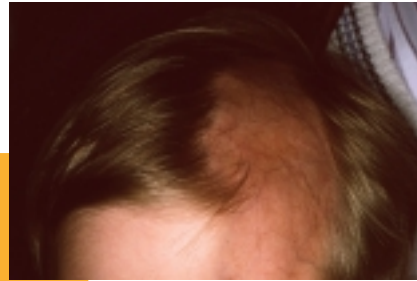Dermatomyositis



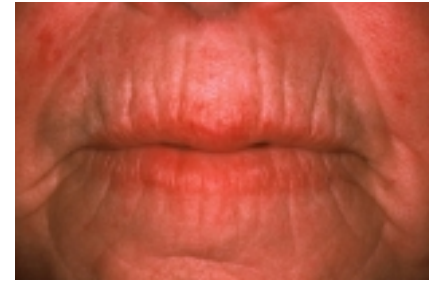Dermatomyositis



Localized morphea



Localized morphea



Systemic sclerosis



search



contents



print



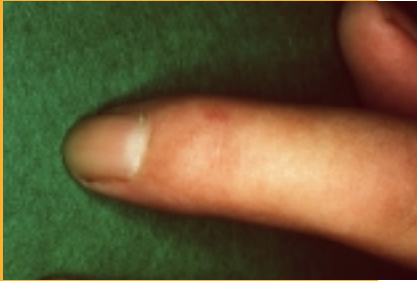last screen viewed



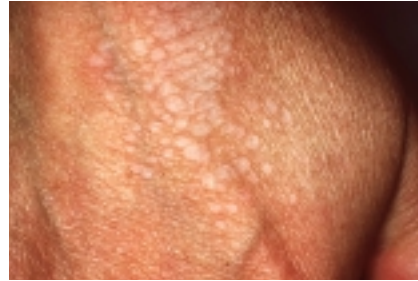back



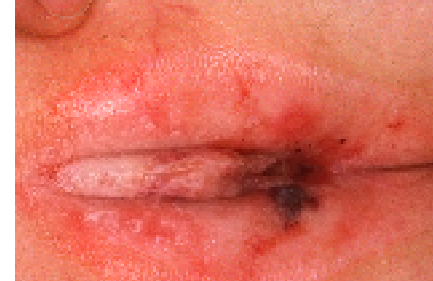next



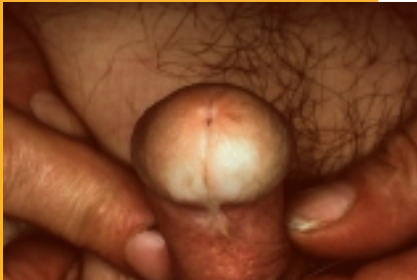Systemic sclerosis



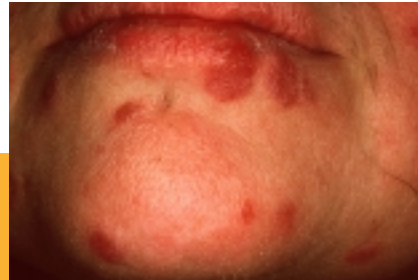Lichen sclerosus



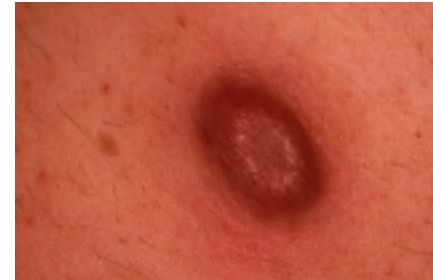Lichen sclerosus



Lichen sclerosus



Sarcoidosis



Sarcoidosis



search



contents



print



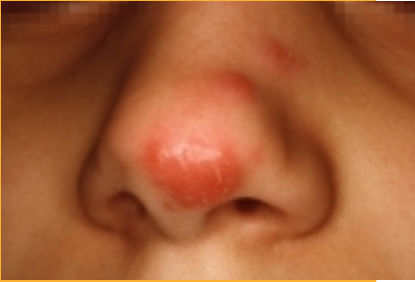last screen viewed



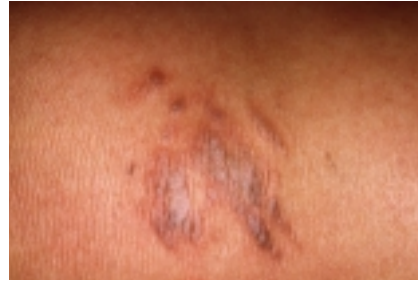back



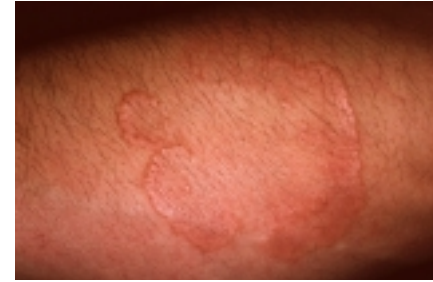next



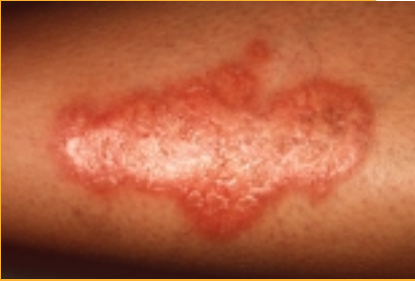Sarcoidosis



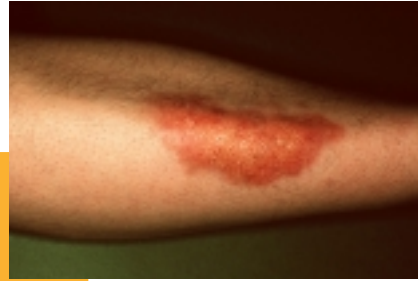Sarcoidosis



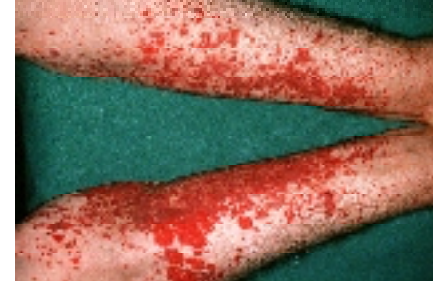Granuloma annulare



Necrobiosis lipoidica



Necrobiosis lipoidica



Vasculitis



search



contents



print



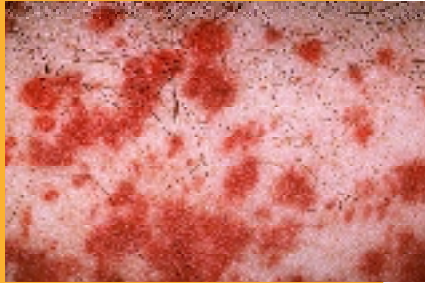last screen viewed



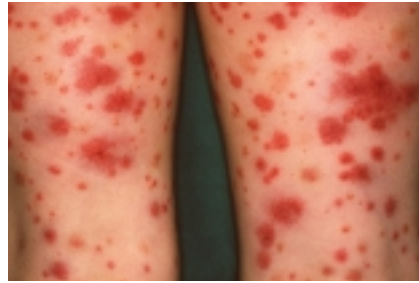
back



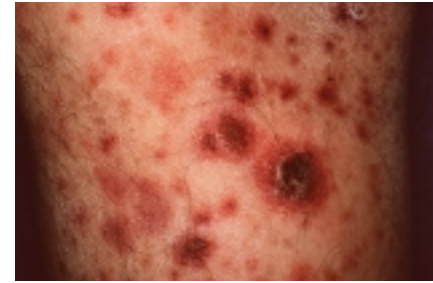
next



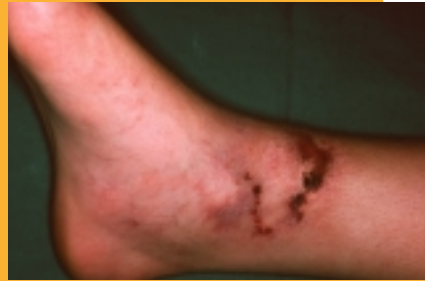Cutaneous vasculitis



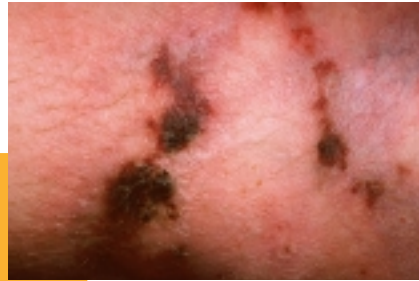Cutaneous vasculitis



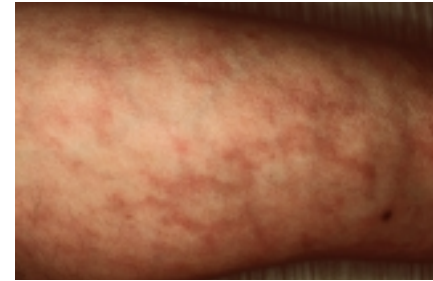Cutaneous vasculitis



Atrophie blanche



Atrophie blanche



Polyarteritis nodosa



search



contents



print



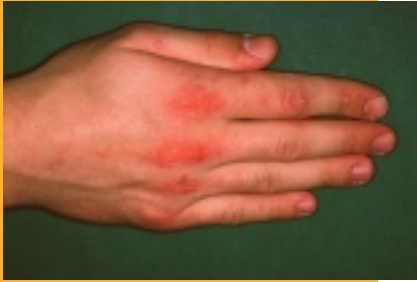last screen viewed



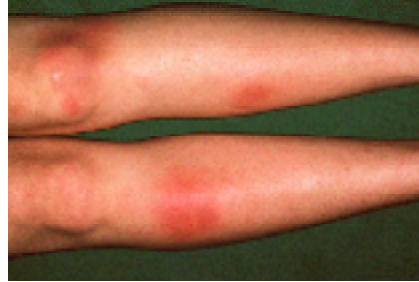back



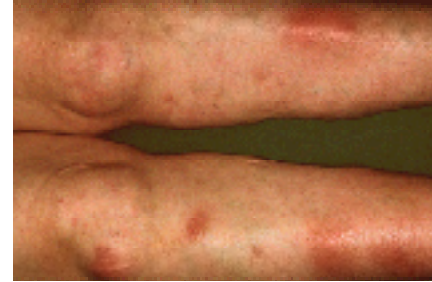
next



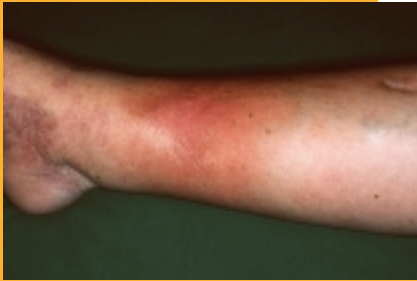Erythema elevatum diutinum



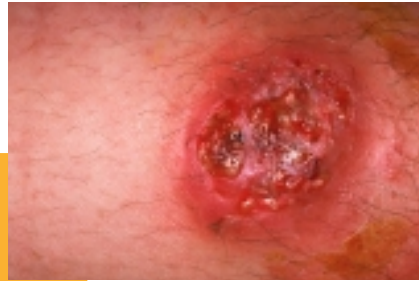Erythema nodosum



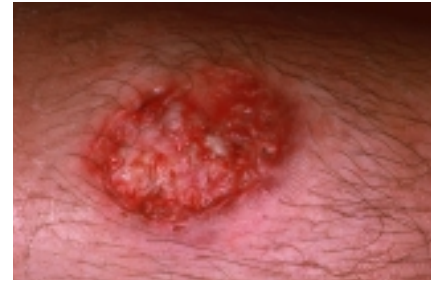Erythema nodosum



Nodular vasculitis



Pyoderma gangrenosum



Pyoderma gangrenosum



search



contents



print



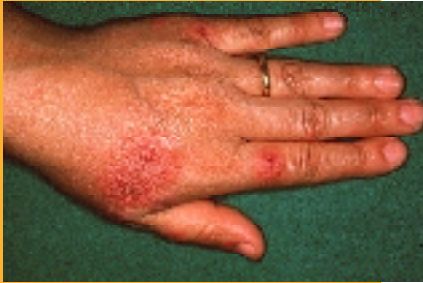last screen viewed



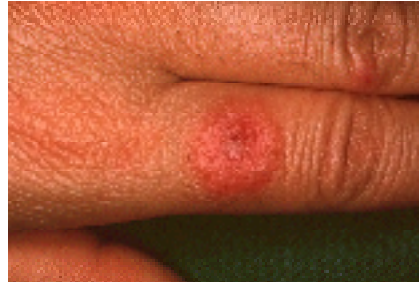back



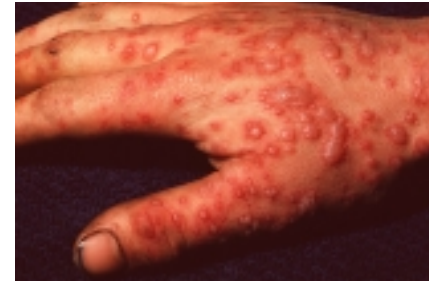next



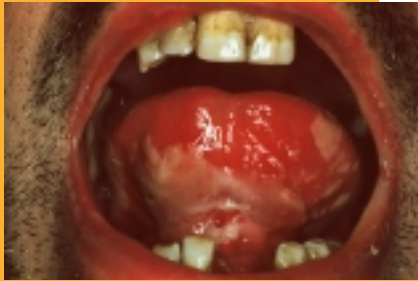Erythema multiforme



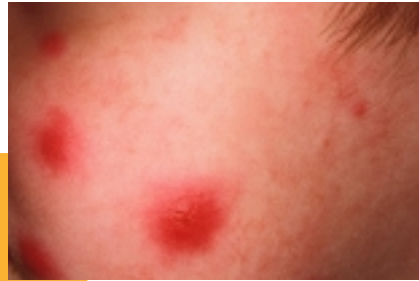Erythema multiforme



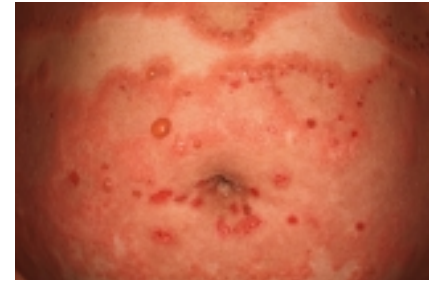
Erythema multiforme



Erythema multiforme



Sweet's syndrome



Bullous pemphigoid



search



contents



print



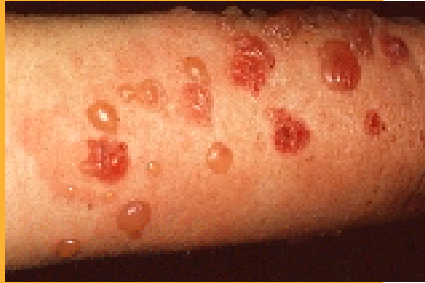last screen viewed



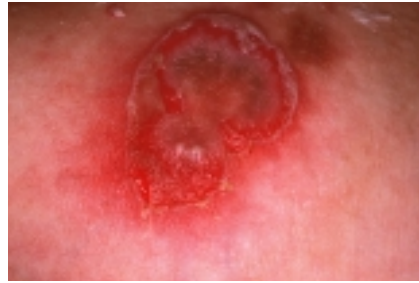back



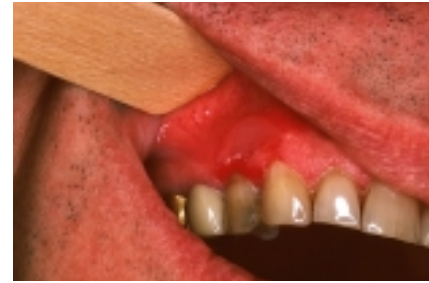next



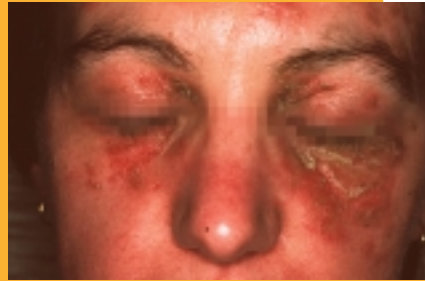Bullous pemphigoid



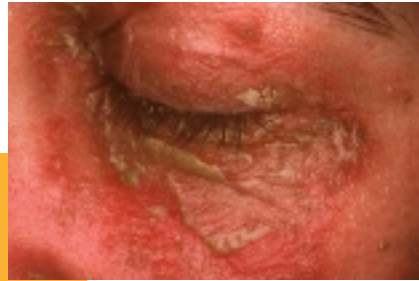Pemphigus vulgaris



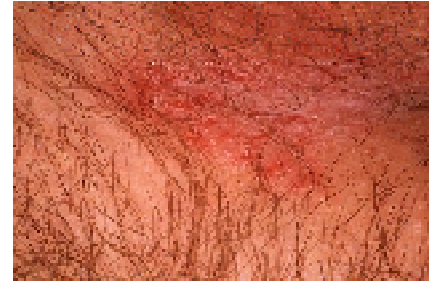Pemphigus vulgaris



Pemphigus erythematosus



Pemphigus erythematosus



Benign familial chronic pemphigus



search



contents



print



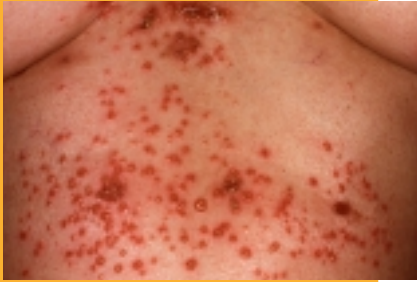last screen viewed



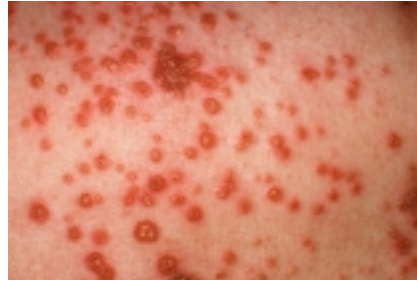back



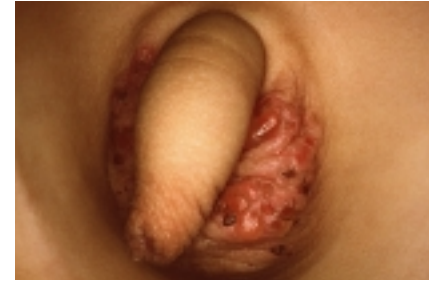next



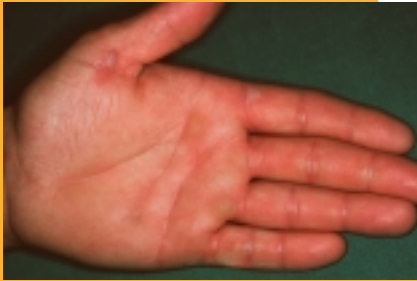Dermatitis herpetiformis



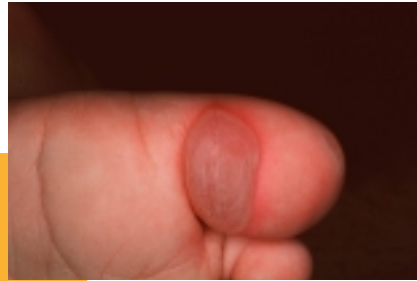Dermatitis herpetiformis



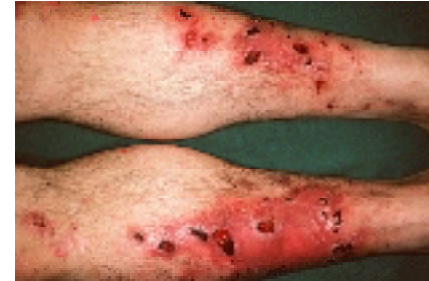Linear IgA bullous disease



Simple epidermolysis bullosa



Simple epidermolysis bullosa



Dystrophic forms of epidermolysis bullosa



search



contents



print



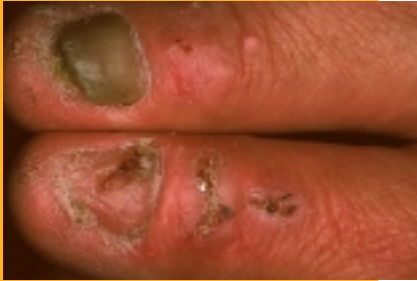last screen viewed



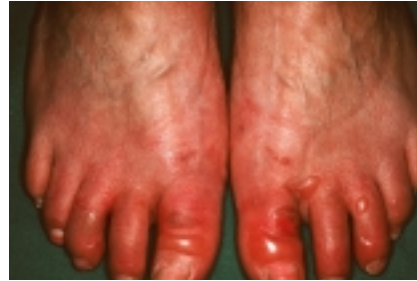back



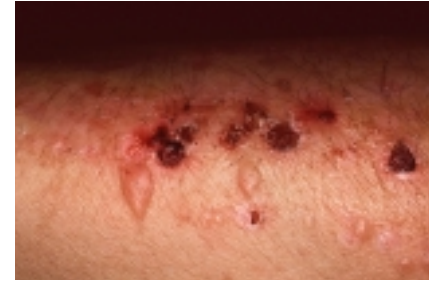next



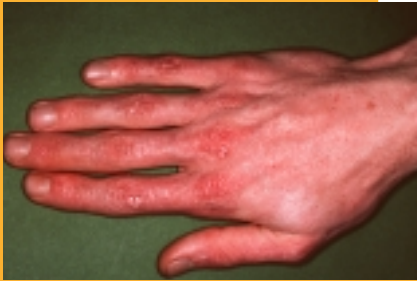Dystrophic forms of epidermolysis bullosa



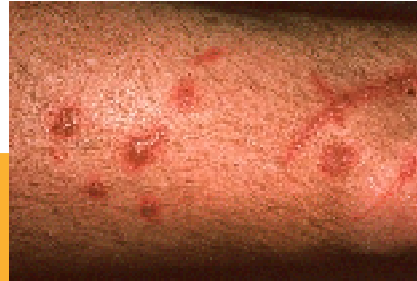Diabetic bullae



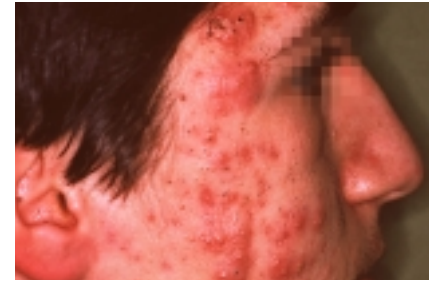Porphyria cutanea tarda



Porphyria cutanea tarda



Bullous phytophotodermatitis



Acne vulgaris



search



contents



print



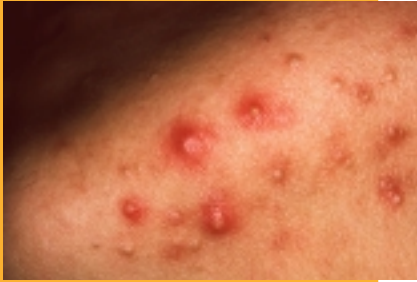last screen viewed



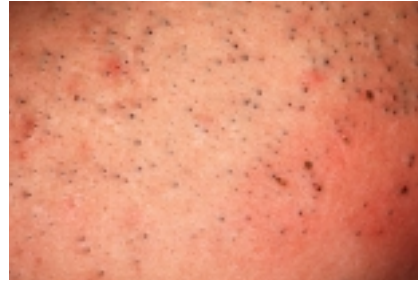back



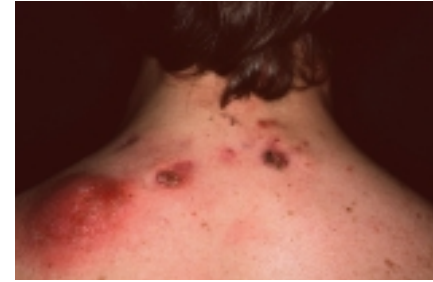next



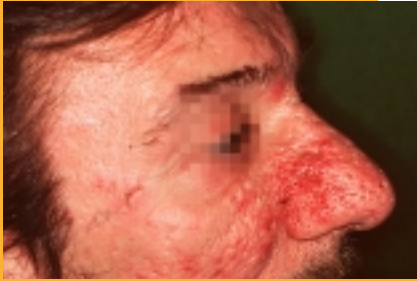Acne vulgaris



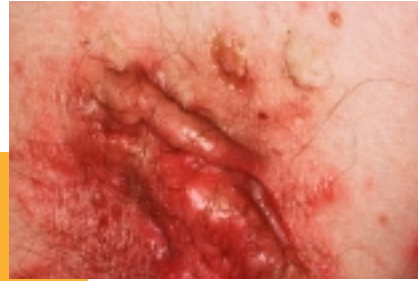Acne vulgaris



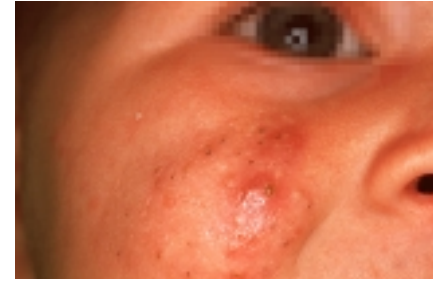
Acne vulgaris



Acne conglobata



Acne conglobata



Infantile acne



search



contents



print



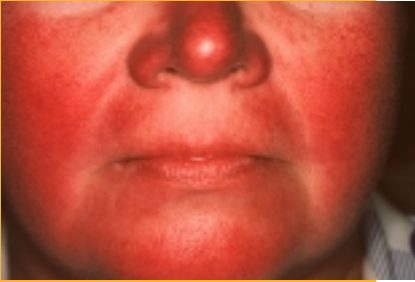last screen viewed



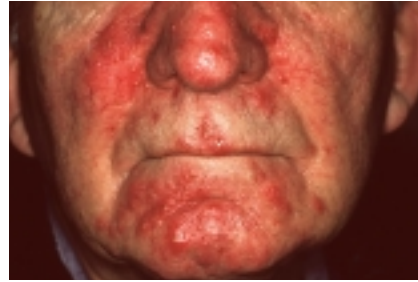back



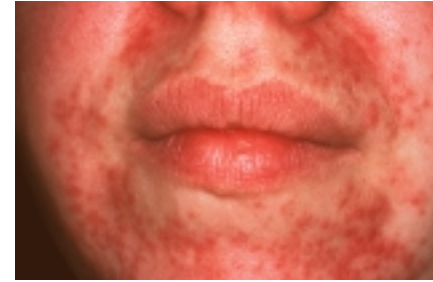next



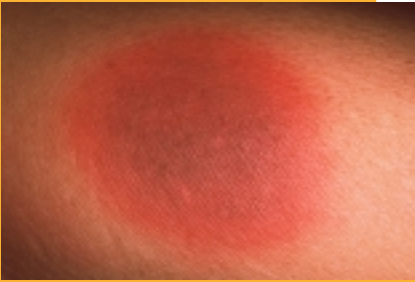Rosacea



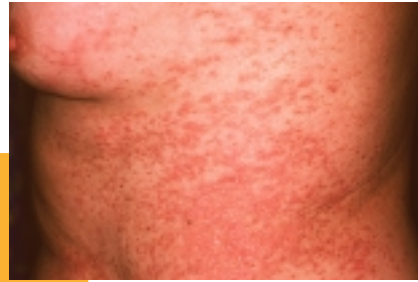Rosacea



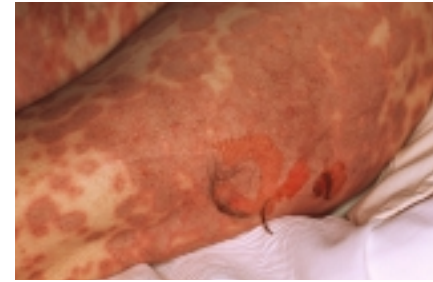Perioral dermatitis



Fixed pigmented erythema



Maculopapular exanthema



Lyell's syndrome



search



contents



print



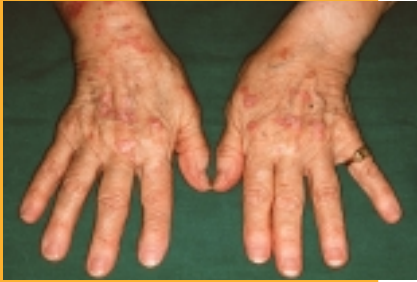last screen viewed



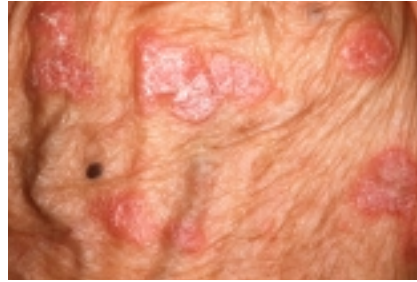
back



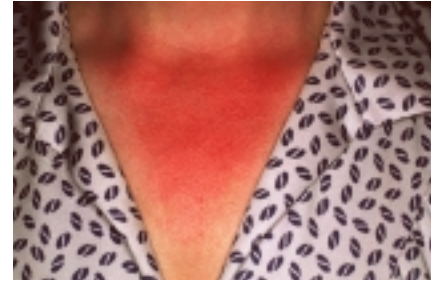next



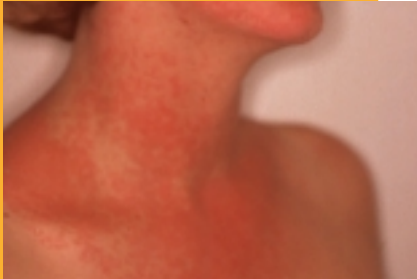Lichenoid eruptions



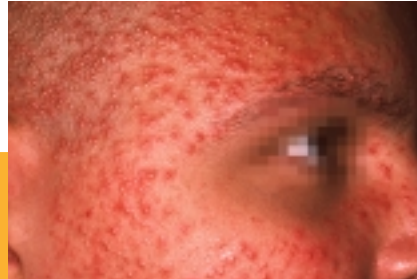Lichenoid eruptions



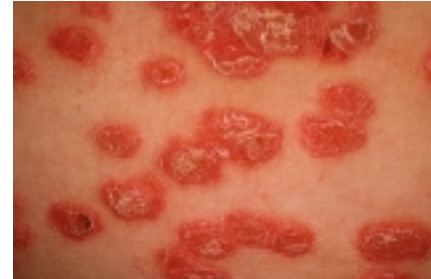Drug-induced phototoxic eruption



Drug-induced photoallergic eruption



Acneiform facial eruption



Psoriatiform eruption



search



contents



print



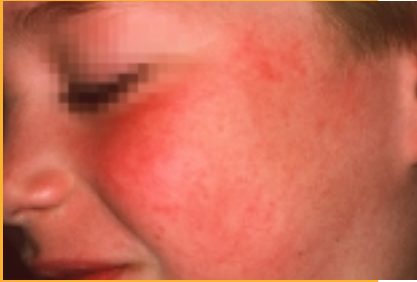last screen viewed



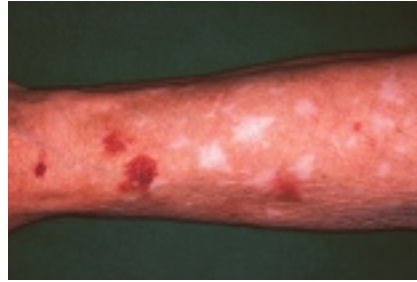back



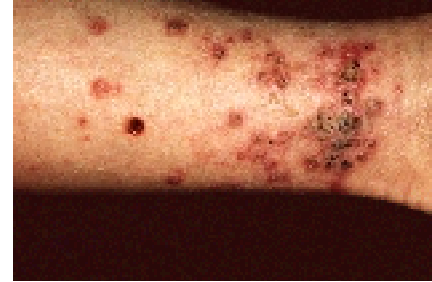next



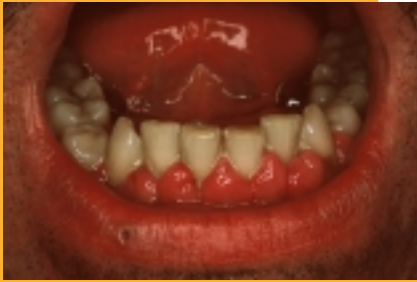Drug-induced lupus



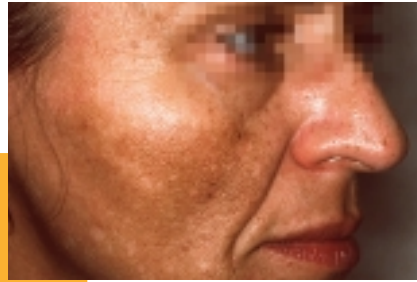Cortisone atrophy



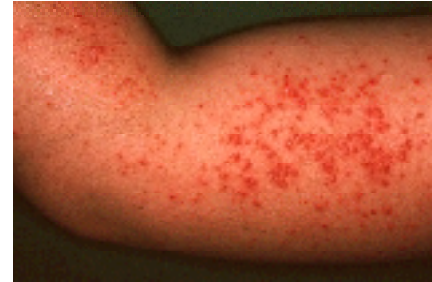Bromide and iodide eruptions



Gingival hyperplasia



Melasma



Benign summer photodermatitis



search



contents



print



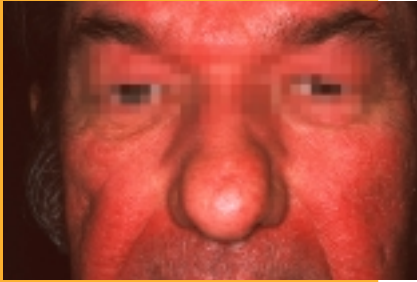last screen viewed



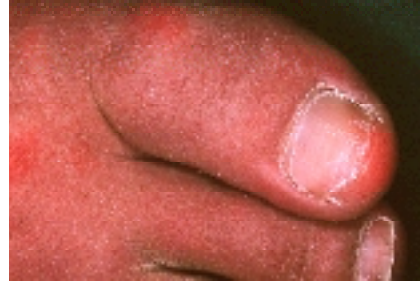back



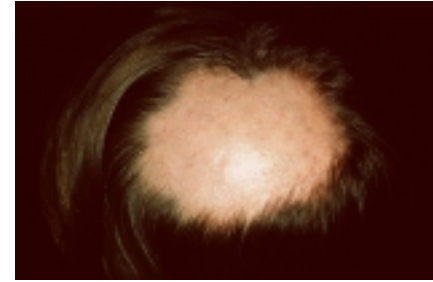next



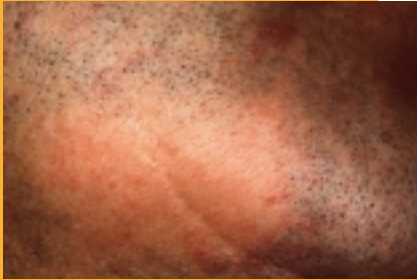Polymorphic light eruption



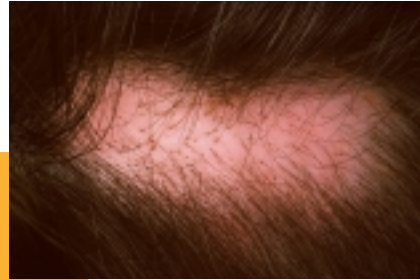Chilblains



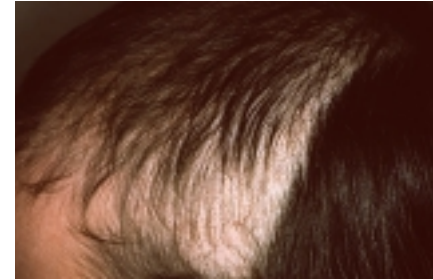Alopecia areata



Alopecia areata



Pseudopelade



Trichotillomania



search



contents



print



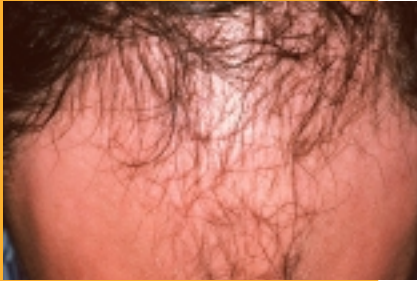last screen viewed



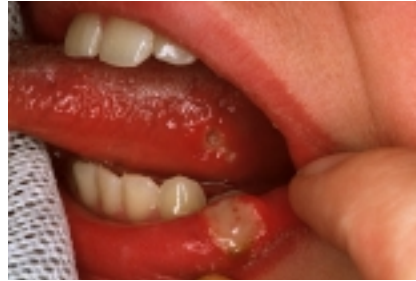back



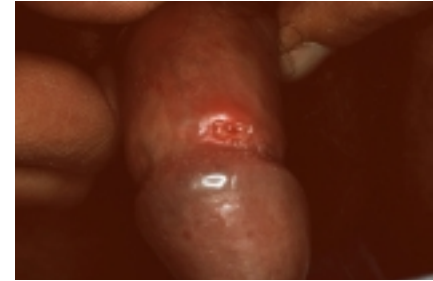next



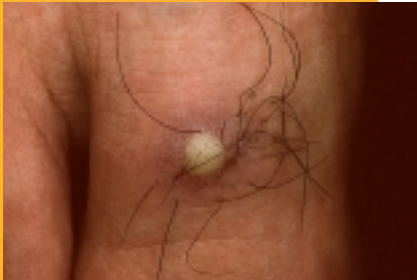Androgenetic alopecia



Aphthae, aphthosis, Behçet's disease



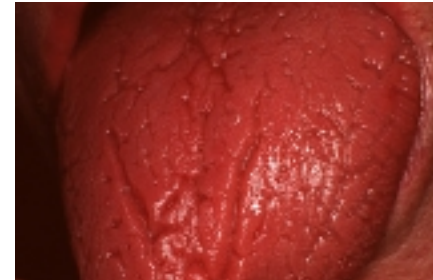Aphthae, aphthosis, Behçet's disease



Aphthae, aphthosis, Behçet's disease



Black hairy tongue



Scrotal / fissured tongue



search



contents



print



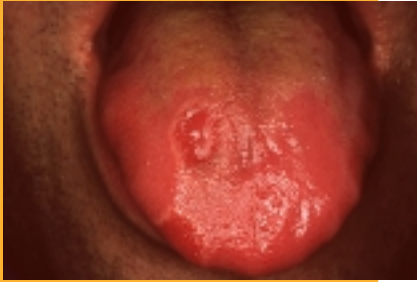last screen viewed



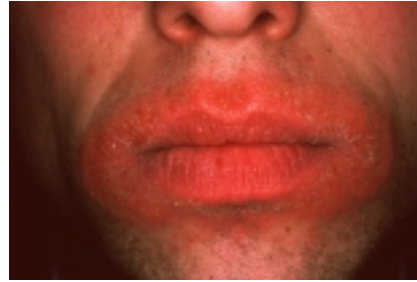back



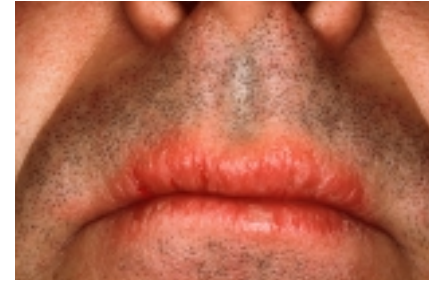next



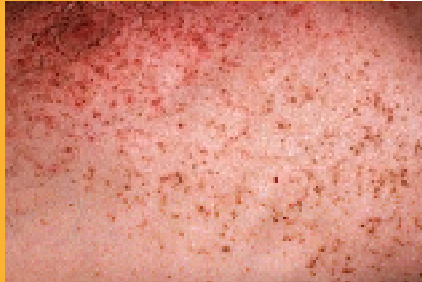Geographic tongue



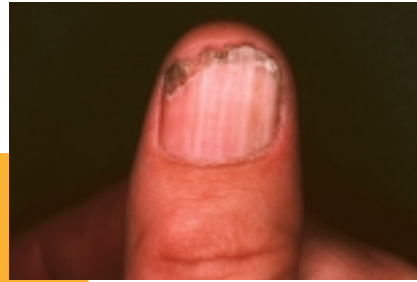Allergic contact cheilitis



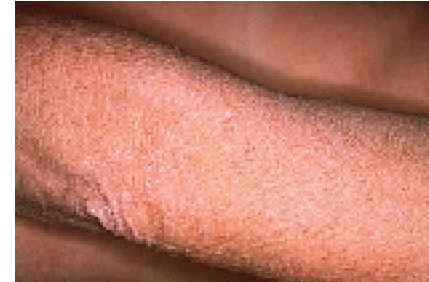Cheilitis caused by systemic use off isotretinoin



Darier's disease



Darier's disease



Ichthyosis vulgaris



search



contents



print



last screen viewed




back



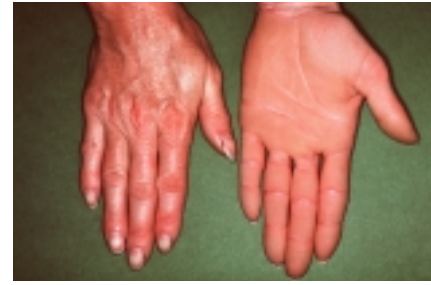next



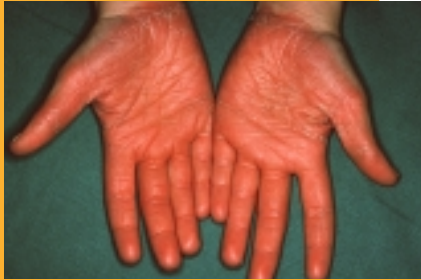Sex-linked (recessive) ichthyosis



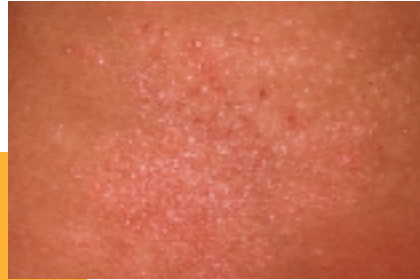Sex-linked (recessive) ichthyosis



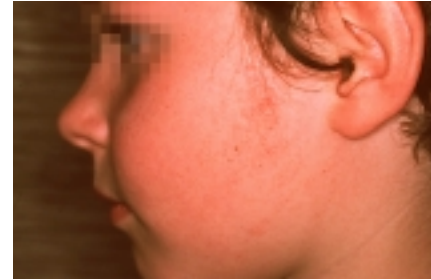Hereditary palmoplantar keratoderma



Pityriasis rubra pilaris



Pityriasis rubra pilaris



Keratosis pilaris



search



contents



print



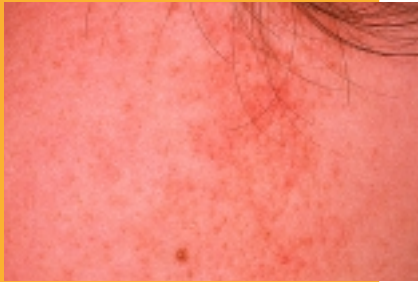last screen viewed



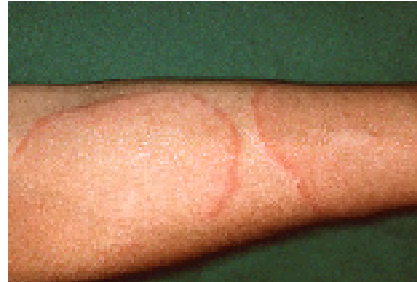back



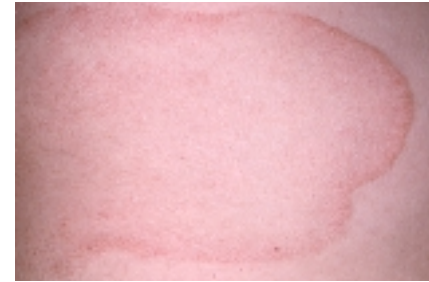next



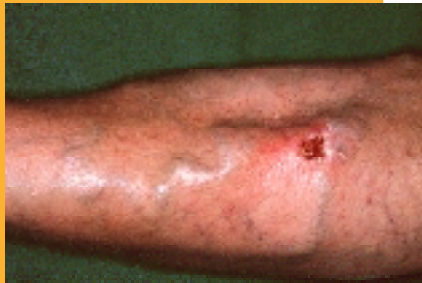Keratosis pilaris



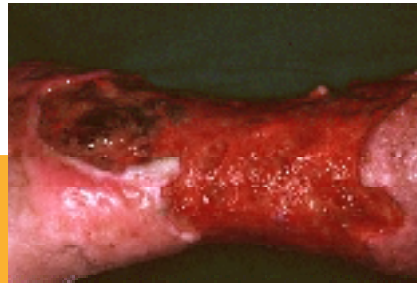
Erythema annulare centrifugum



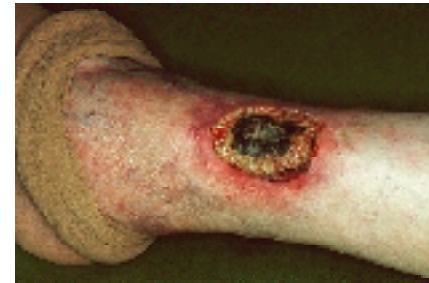Erythema annulare centrifugum



Venous leg ulcer



Venous leg ulcer



Ischaemic (arterial) leg ulcer



search



contents



print



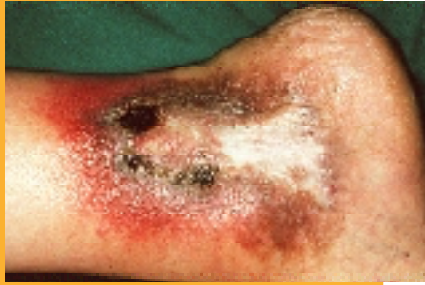last screen viewed



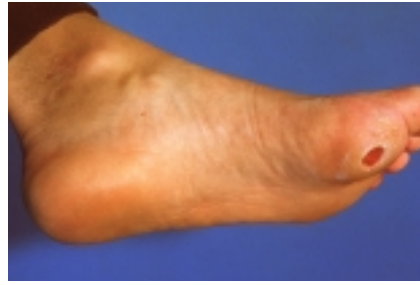back



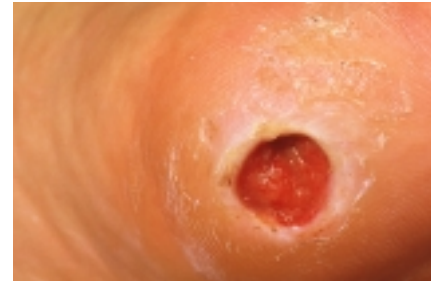next



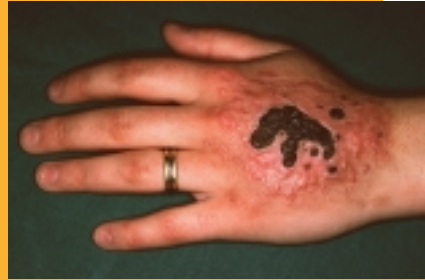Ulcer caused by capillaritis



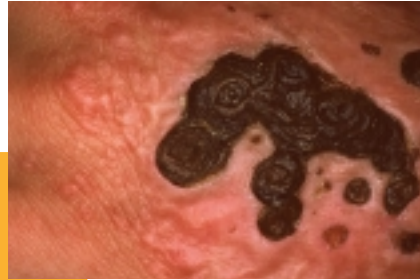Neurotrophic leg ulcer



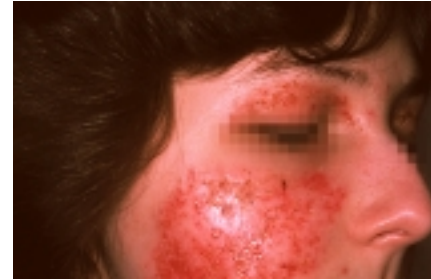Neurotrophic leg ulcer



Skin self-mutilation simulated disease



Skin self-mutilation simulated disease



Self-mutilation, pathomimicry



search



contents



print



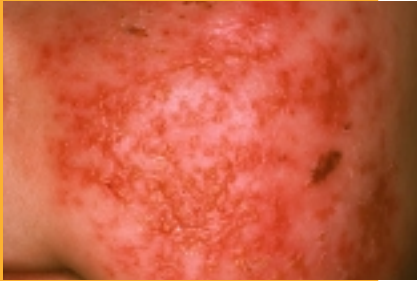last screen viewed



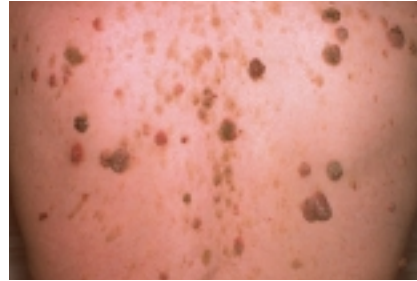back



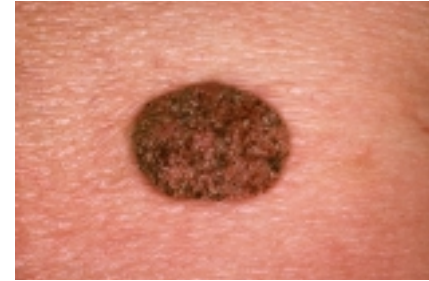
next



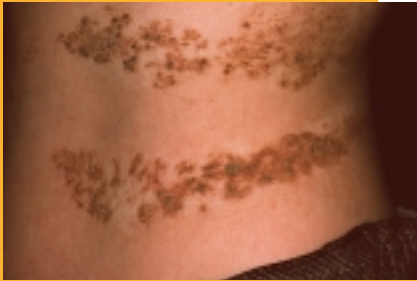Self-mutilation,
pathomimicry



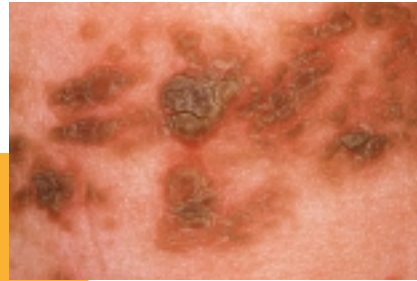
Seborrheic keratosis / wart



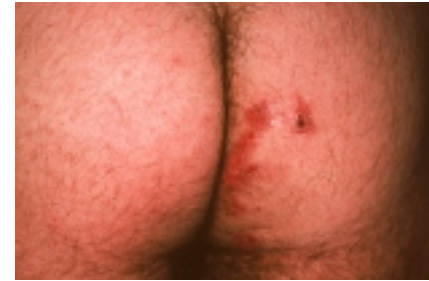Seborrheic keratosis / wart



Verrucous epidermal naevus



Verrucous epidermal naevus



Inflammatory linear
verrucous epidermal naevus



search



contents



print



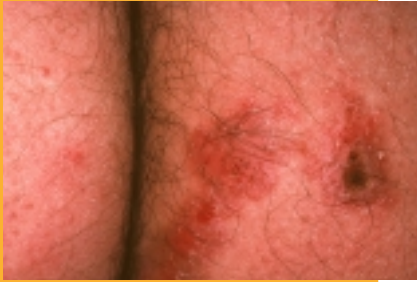last screen viewed



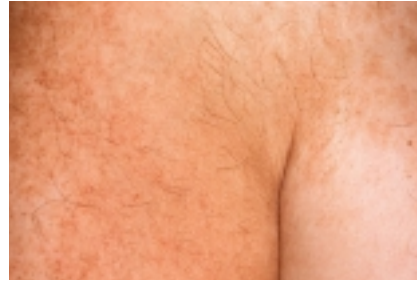back



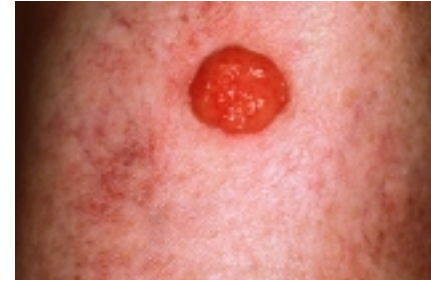next



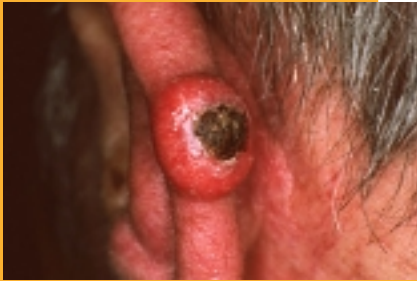Inflammatory linear verrucous epidermal naevus



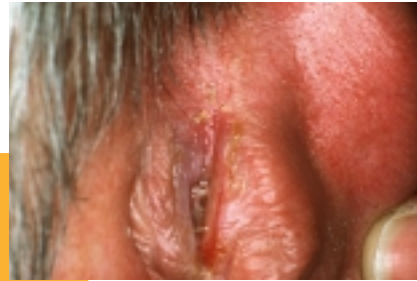Becker's naevus



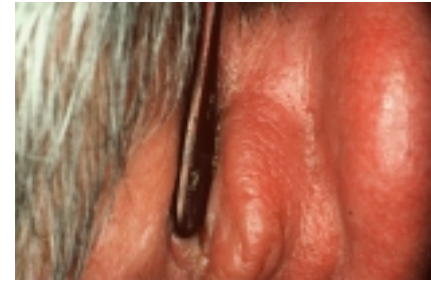Clear cell acanthoma



Kerato-acanthoma



Spectacle frame acanthoma



Spectacle frame acanthoma



search



contents



print



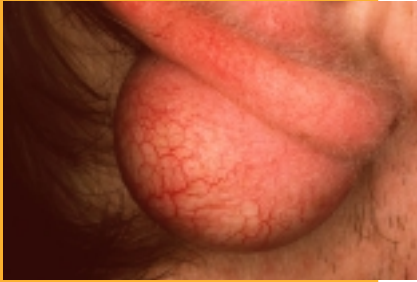last screen viewed



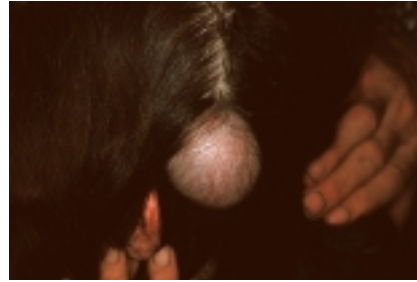back



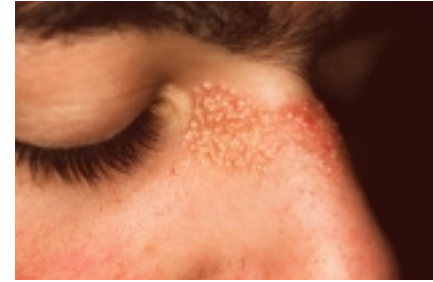next



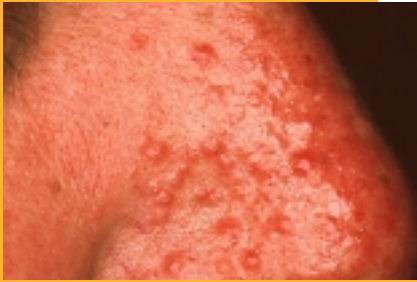Epidermoid cyst



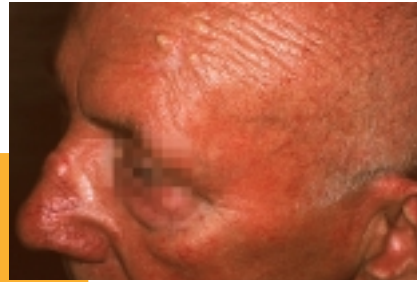Trichilemmal cyst



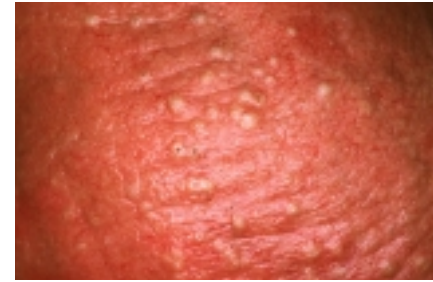Milia



Trichoepithelioma



Senile sebaceous adenoma



Senile sebaceous adenoma



search



contents



print



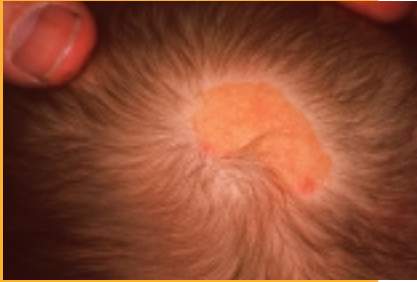last screen viewed



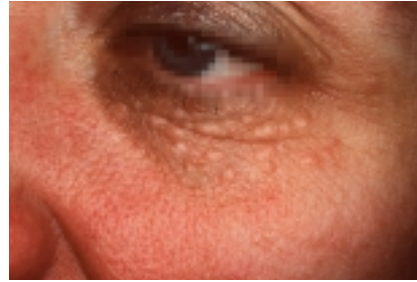back



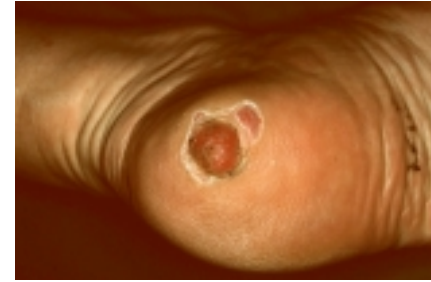next



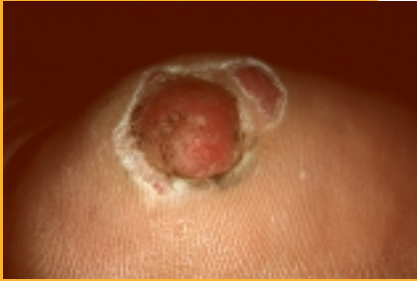Jadassohn's sebaceous naevus



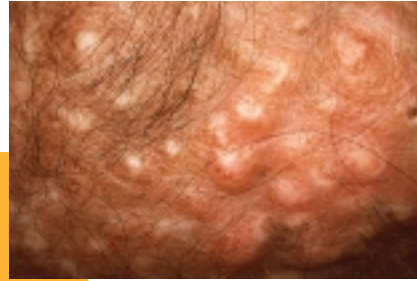Syringoma



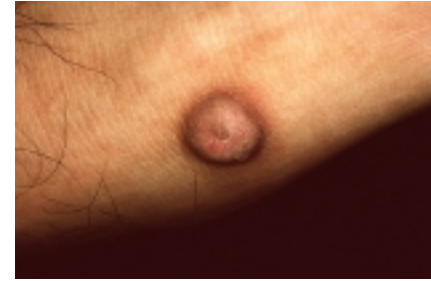Eccrine poroma



Eccrine poroma



Cylindroma



Dermatofibroma



search



contents



print



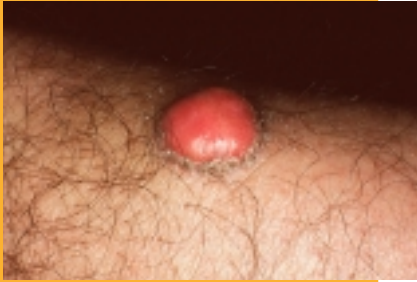last screen viewed



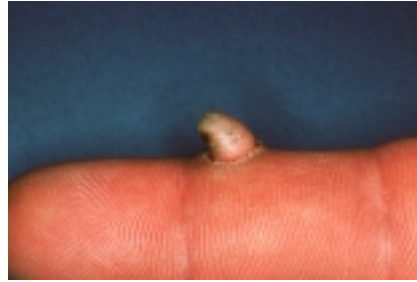back



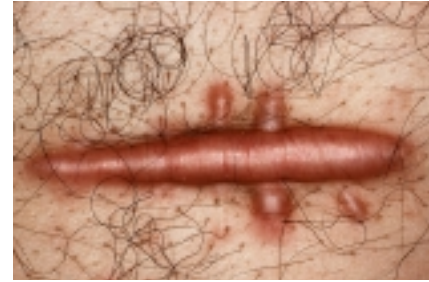next



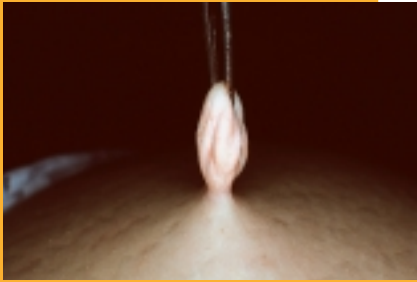Dermatofibroma



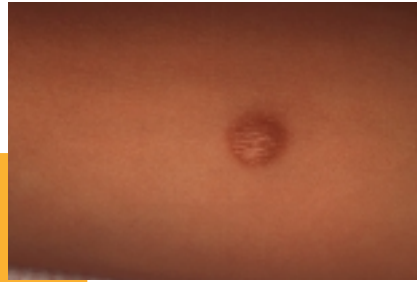Acquired digital fibrokeratoma



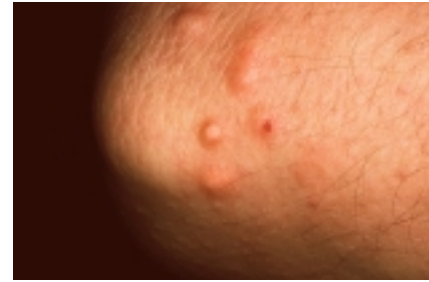Keloid



Skin tag



Juvenile xanthogranuloma



Tuberous xanthoma



search



contents



print



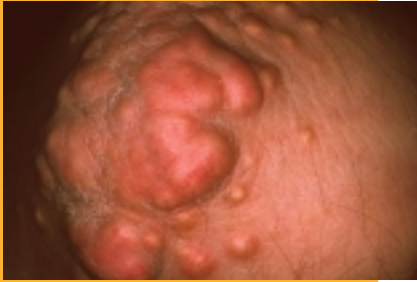last screen viewed



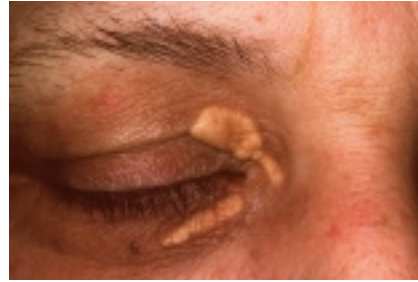back



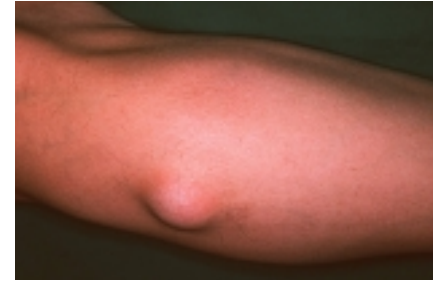next



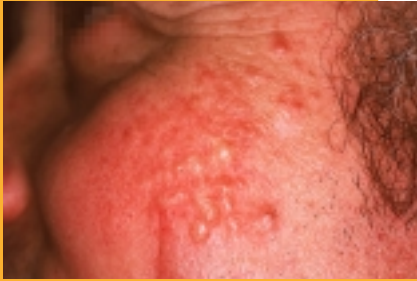Tuberous xanthoma



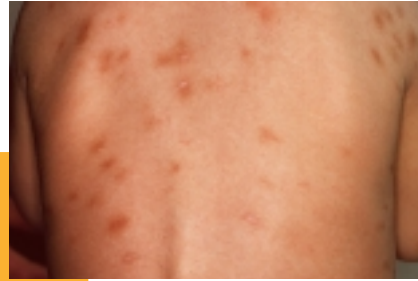Xanthelasma palpebrarum



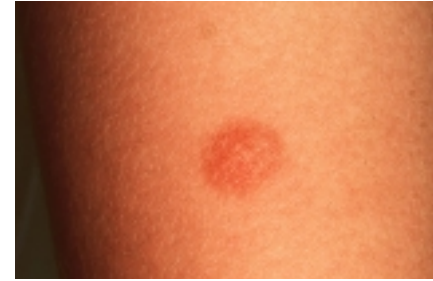Lipoma



Leiomyoma



Cutaneous mastocytosis



Cutaneous mastocytosis



search



contents



print



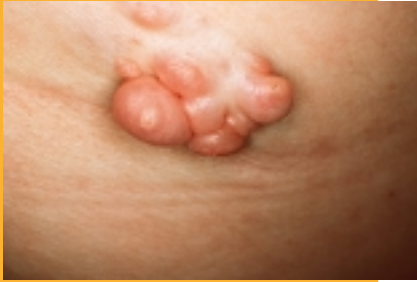last screen viewed



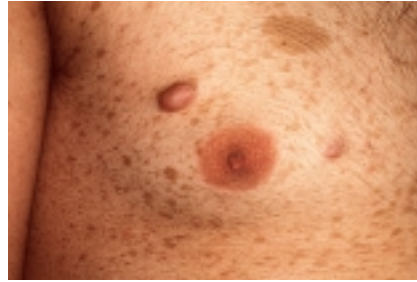back



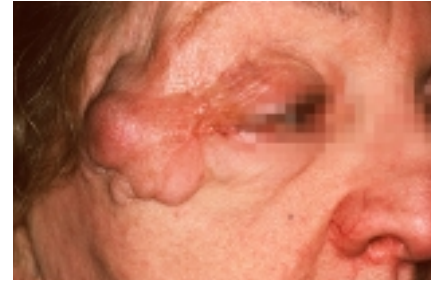next



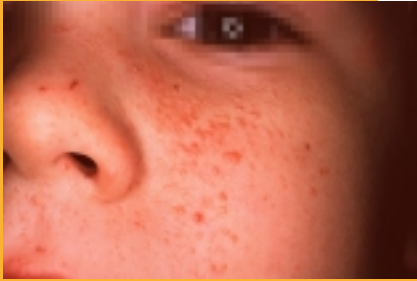Neural crest diseases



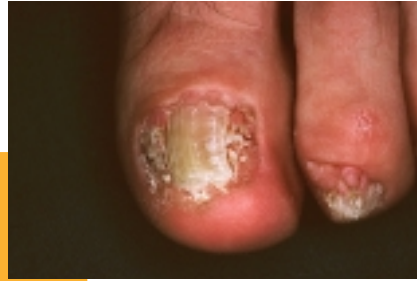Neural crest diseases



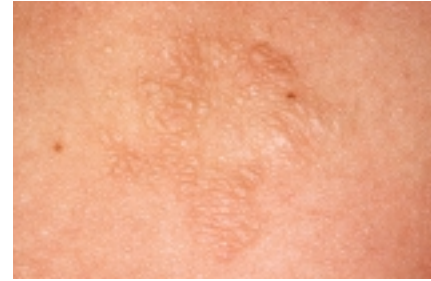Neural crest diseases



Neural crest diseases



Neural crest diseases



Neural crest diseases



search



contents



print



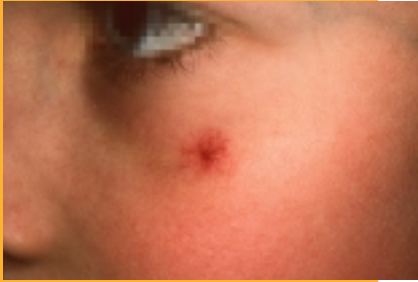last screen viewed



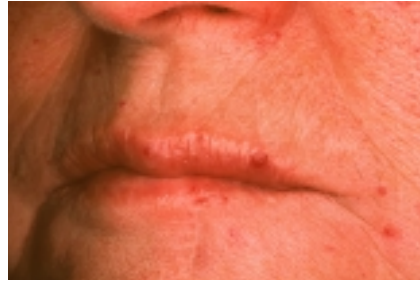back



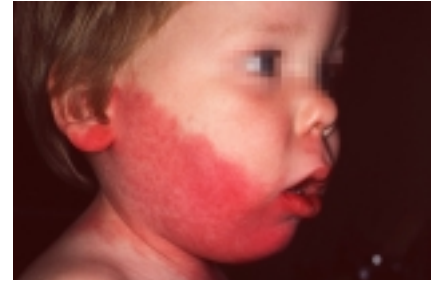next



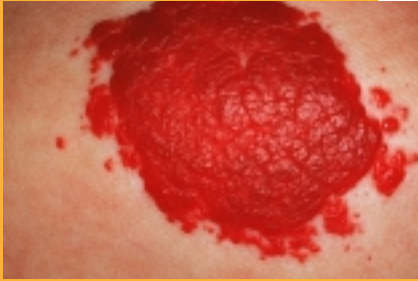Angioma



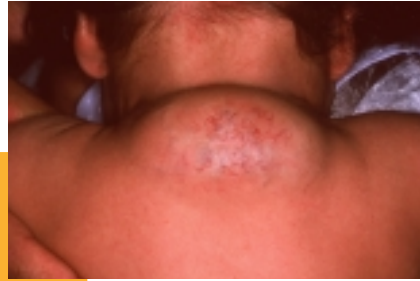
Angioma



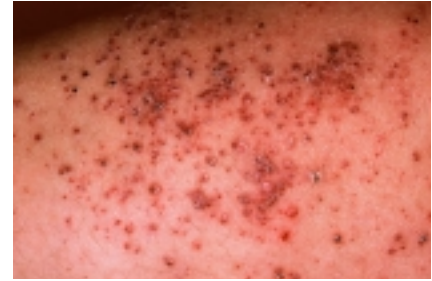Angioma



Angioma



Angioma



Angioma



search



contents



print



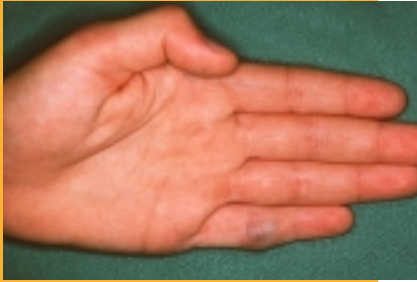last screen viewed



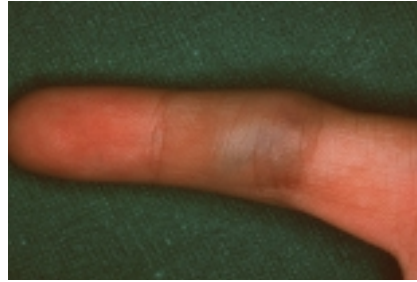
back



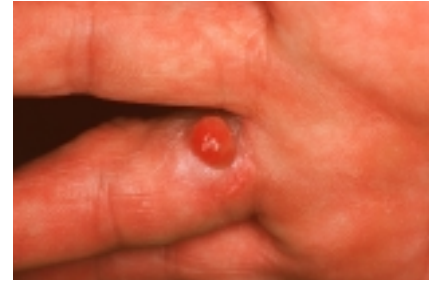next



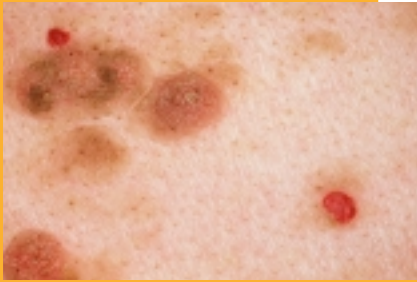Angioma



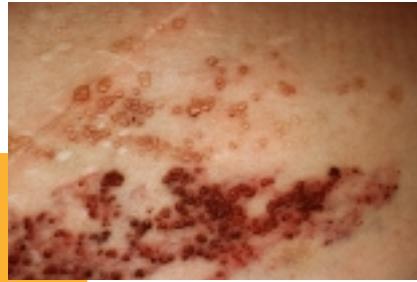Angioma



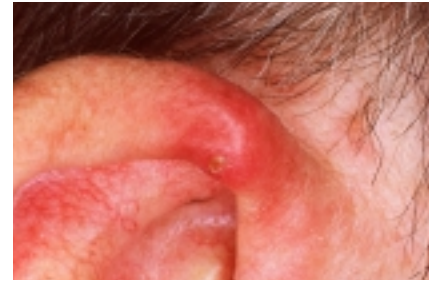Angioma



Angioma



Lymphangioma



Chondrodermatitis nodularis helices



search



contents



print



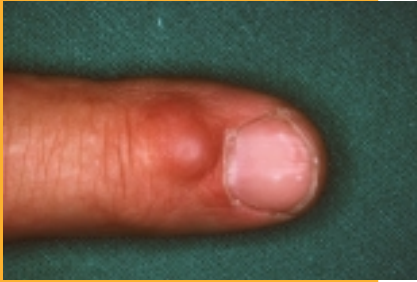last screen viewed



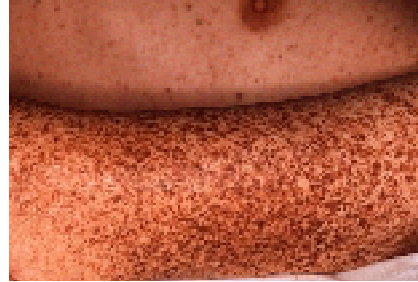back



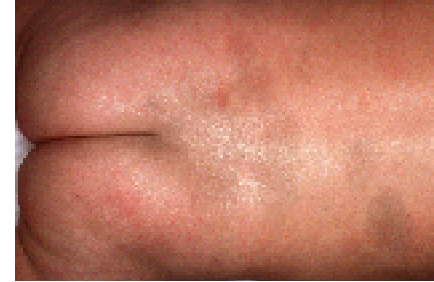next



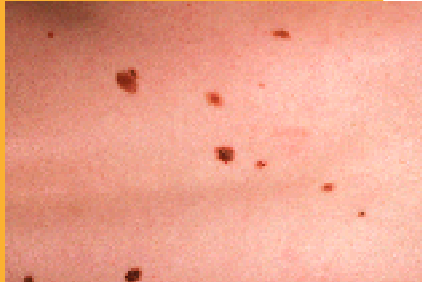Muroid pseudocyst



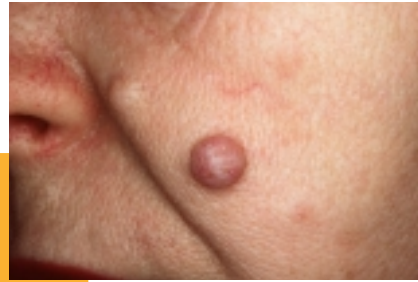Lentigo



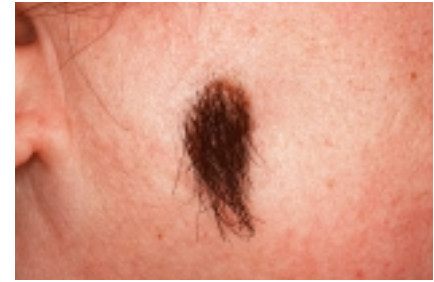Mongolian spot



Melanocytic naevi



Melanocytic naevi



Hairy melanocytic naevus



search



contents



print



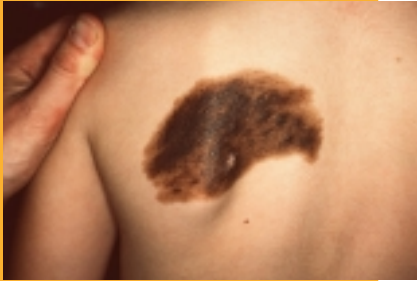last screen viewed



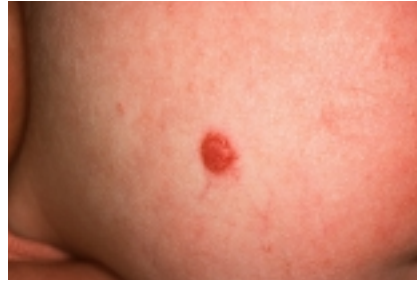back



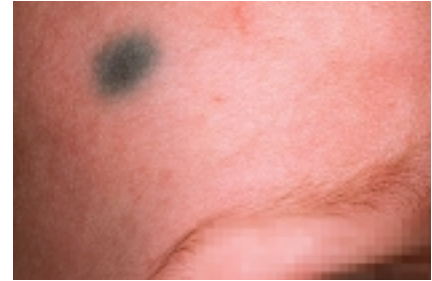next



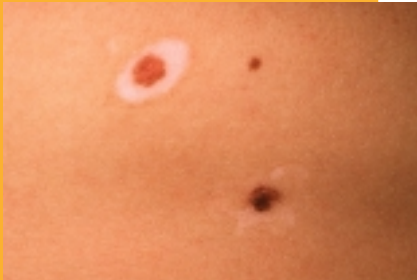Congenital pigmented naevus



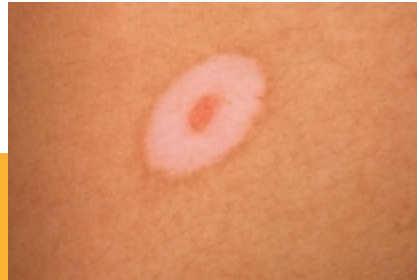Spitz naevus (juvenile)



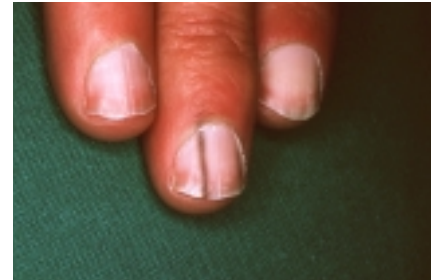Blue naevus



Halo naevus



Halo naevus



Naevus of the nails



search



contents



print



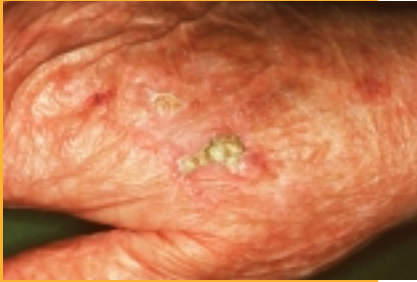last screen viewed



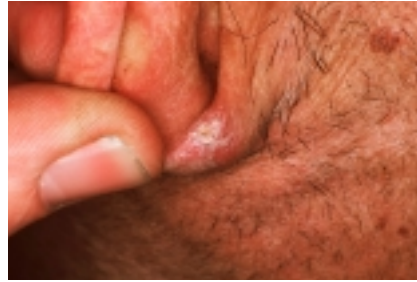back



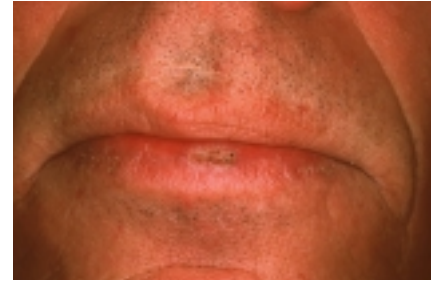next



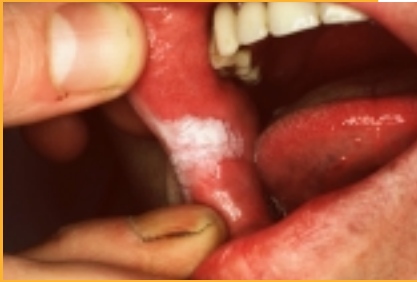Solar keratoses



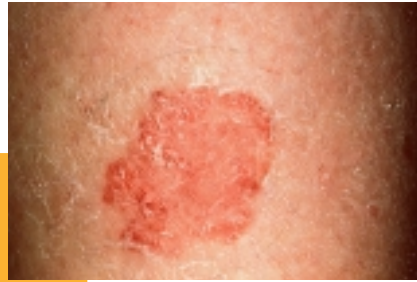Solar keratoses



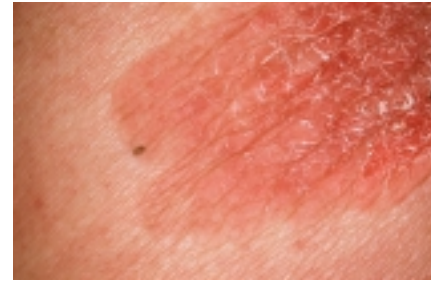Actinic cheilitis



Leucoplakia



Bowen's disease



Bowen's disease



search



contents



print



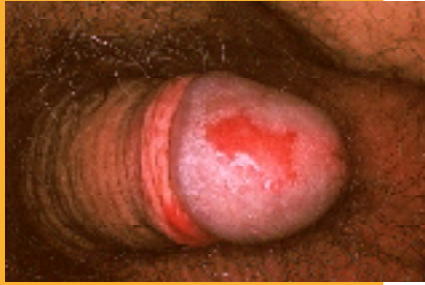last screen viewed



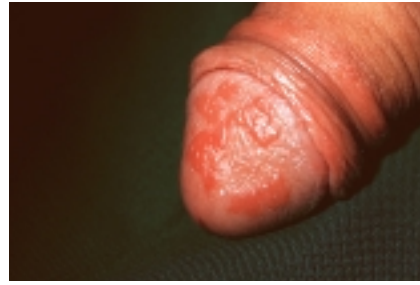back



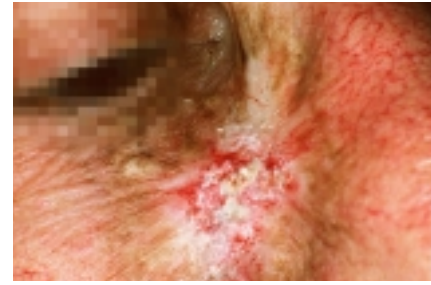next



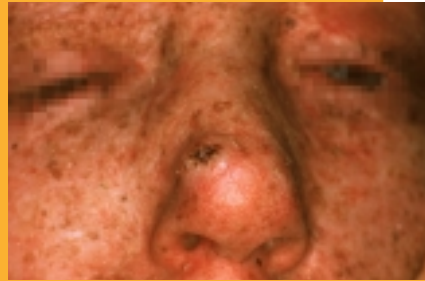Erythroplasia of queyrat



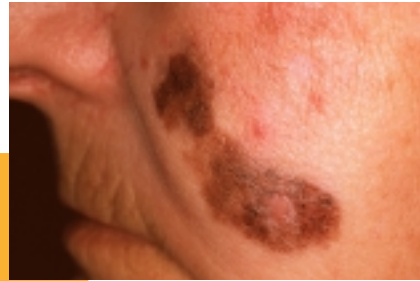Bowenoid papulosis



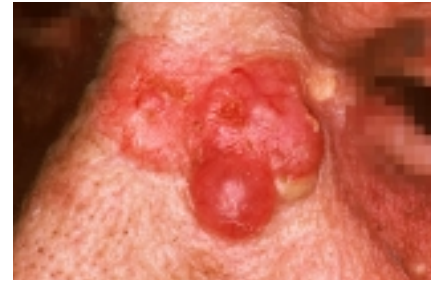Radiodermatitis



Xeroderma pigmentosum



Dubreuilh's melanosis



Nodular basal cell carcinoma



search



contents



print



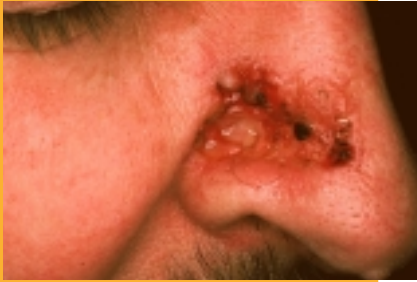last screen viewed



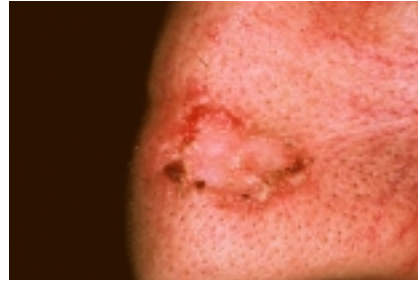back



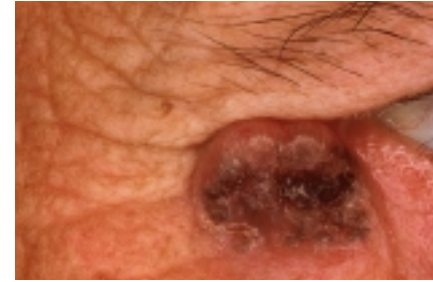
next



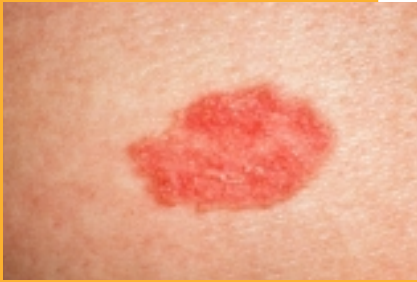Rodent ulcer



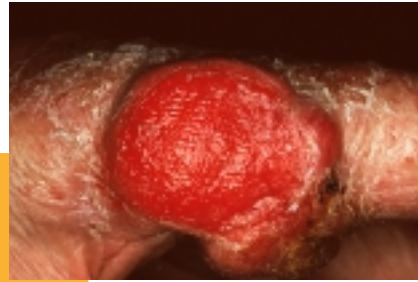
Flat cicatricial basal cell carcinoma



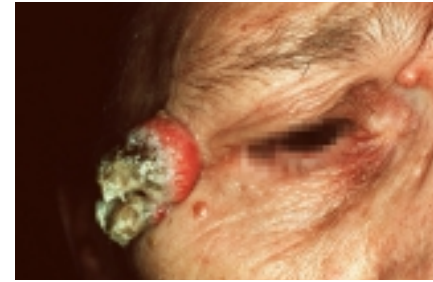Pigmented basal cell carcinoma



Pagetoid basal cellular carcinoma



Squamous cell carcinomas



Squamous cell carcinoma of the face



search



contents



print



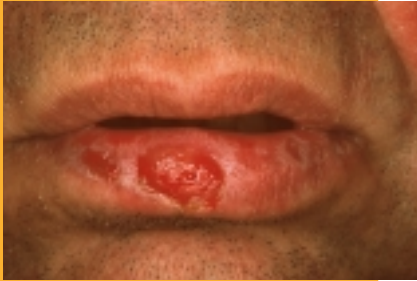last screen viewed



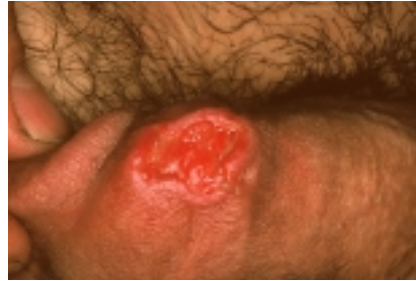back



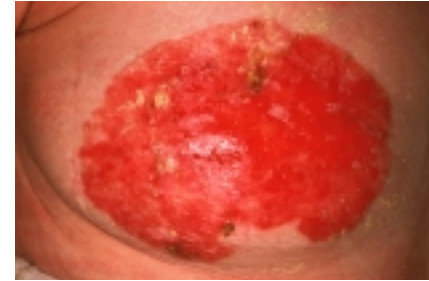
next



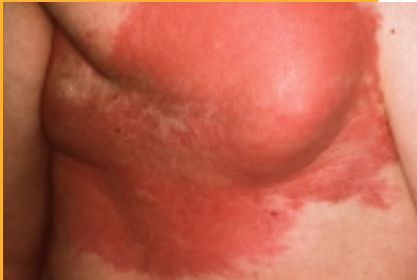Squamous cell carcinoma of the lower lip



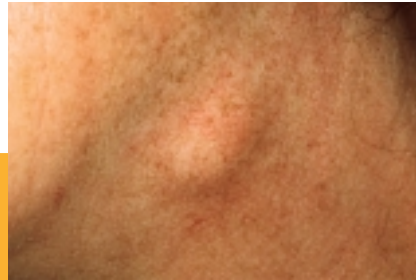Squamous cell carcinoma of the penis



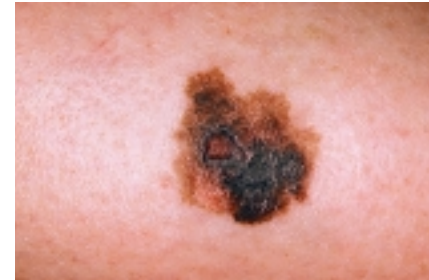Paget's disease



Cutaneous metastases



Cutaneous metastases



Melanoma (malignant)



search



contents



print



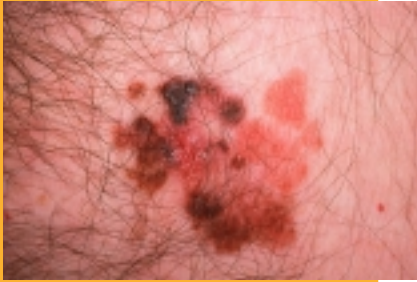last screen viewed



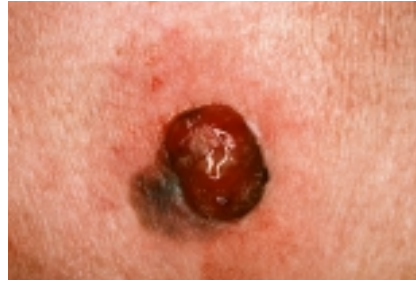back



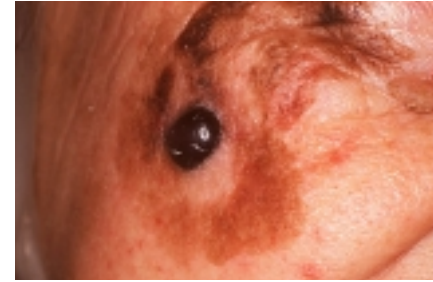
next



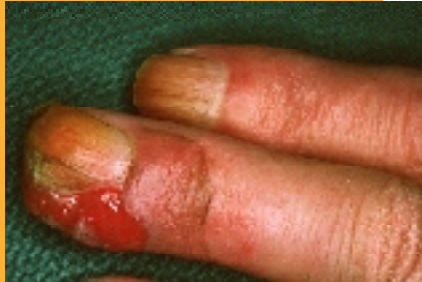Superficial spreading melanoma



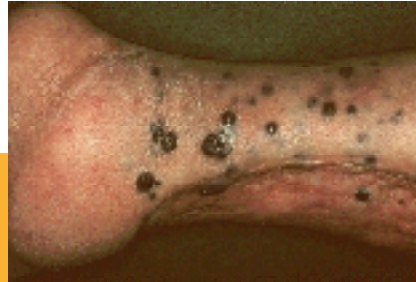Nodular melanoma



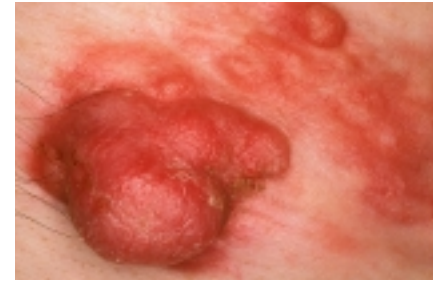Melanoma over Dubreuilh's melanosis precancerosa



Acral lentiginous melanoma



Melanoma metastases



Dermatofibrosarcoma protuberans



search



contents



print



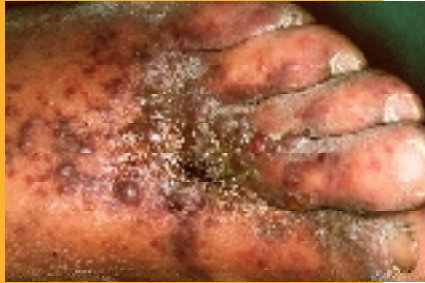last screen viewed



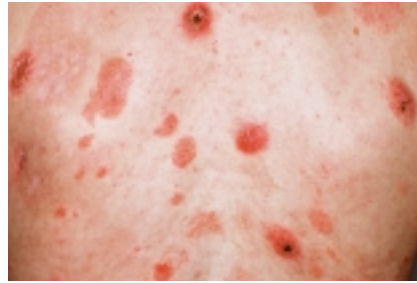back



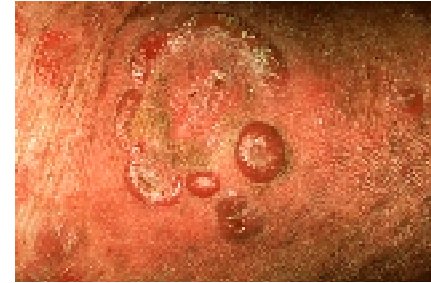
next



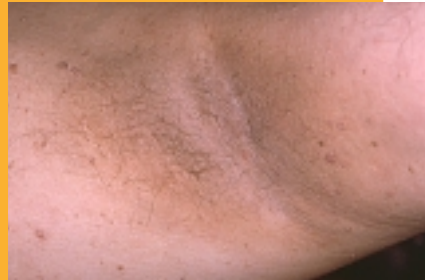Kaposi's angiosarcoma



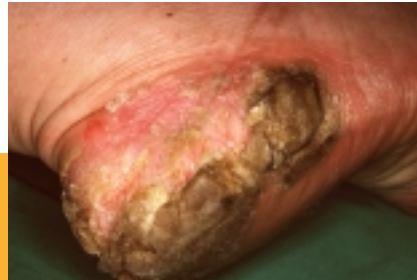Malignant lymphomas - mycosis fungoides



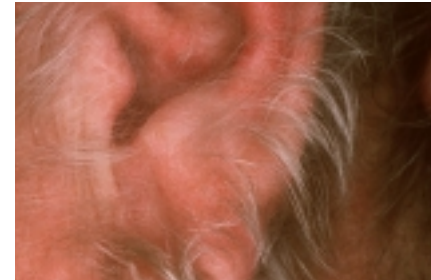Malignant lymphomas - mycosis fungoides



Paraneoplastic syndromes



Bazex's paraneoplastic acrokeratosis



Hypertrichosis lanuginosa



search



contents



print



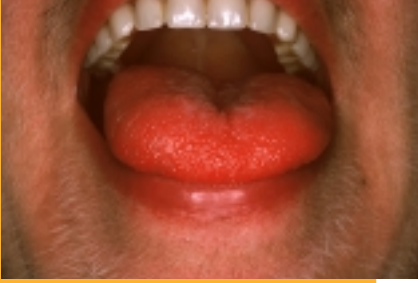
last screen viewed



back



next



Hypertrichosis lanuginosa



search



contents



print



last screen viewed



back



next